



Orthodontic treatment as a possible trigger of periodontal disease

Ann Lin¹

¹ University of Pittsburgh School of Dental Medicine, Pittsburgh PA, USA

Abstract

Background: Periodontal disease leads to the deterioration of oral health, including loss of teeth and its supporting structures. It has been established that the cause of this disease is multifactorial, indicating that both genes and environmental factors are intertwined with the formation and progression of periodontal disease. **Case Description:** Here we discuss the possibility of orthodontic treatment serving as a trigger to an early development of periodontal disease in a patient who has a family history of periodontitis. Between debonding at age 17.5 years and age 28, the patient experienced gradual general loss of attachment on the mandibular arch with the left mandibular canine having exaggerated attachment loss. Between age 28 and 29 years, the patient experienced exacerbated loss of attachment at both mandibular canines. **Practical Implications:** The occurrence of attachment loss during and after orthodontic treatment should not be overlooked. It is crucial for orthodontists to obtain a family history of periodontal disease and carefully monitor patient's periodontal conditions throughout the treatment.

Citation: Lin, A. (2016) Orthodontic Treatment as a Possible Trigger of Periodontal Disease. Dentistry 3000. 1:a001
doi:10.5195/d3000.2016.47
Received: May 1, 2016
Accepted: May 5, 2016
Published: June 7, 2016
Copyright: ©2016 Lin A. This is an open access article licensed under a Creative Commons Attribution Work 4.0 United States License.
Email: apl22@pitt.edu

Introduction

It has been shown that periodontal disease, to be more specific, periodontitis, affects 30-50% of the population in the United States [1]. This disease is triggered by the imbalance of local factors, i.e. bacteria in the oral cavity, and systemic conditions of the individual. Despite its etiology being bacterial infection such as *Aggregatibacter actinomycetemcomitans*, *Porphyromonas gingivalis*, *Prevotella intermedia*, etc., other factors such as familial aggregation including genetic and environmental elements play a major role in the development of periodontal disease.

Signs and symptoms of early stage periodontal disease (i.e. gingivitis) will progress to the more advanced periodontitis if a patient is susceptible to periodontal disease in aspects of genetics, local factors in the oral cavity, oral hygiene, environment, systemic health conditions, etc. Alveolar bone and teeth loss are the end results of periodontal disease if left untreated or unattended. Teeth loss due to periodontal disease has detrimental effects because the patient may not be the best candidate for complete dentures due to lack of mechanical support and retention from the resorbed alveolar ridges. Dental implants placed in periodontal pa-

tients may not have the desired success or survival rate [2].

Periodontal disease has serious implications not only because a continuous bone loss will eventually lead tooth loss but also because it is a risk factor for cardiovascular disease and other major systemic diseases such as diabetes mellitus. It has been investigated that periodontal patients may be low in their neutrophil cell counts and/or dysfunction of neutrophils so that the body cannot provide protection to the periodontium against bacteria [1].



New articles in this journal are licensed under a Creative Commons Attribution 4.0 United States License.



This journal is published by the [University Library System](#), [University of Pittsburgh](#) as part of its [D-Scribe Digital Publishing Program](#) and is cosponsored by the [University of Pittsburgh Press](#).

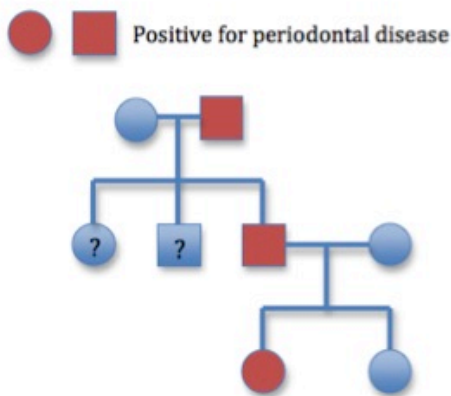


Figure 1. Pedigree chart of periodontal disease over three generations in the patient's family. Affected patients are shown in red on the chart. It is unclear whether the patient's uncle and aunt are affected. However, the pedigree shows a trend of periodontal disease in every generation, mimicking an autosomal dominant mode of inheritance.

Having atherosclerotic problems already, cardiovascular patients are further in danger since bacteria contributing to periodontal disease such as *Streptococcus sanguis* and *Porphyromonas gingivalis* can enter the blood stream and can adhere to atherosclerotic plaques inducing blood clots. Patients with diabetes are at an increased risk of developing periodontal disease because of the increase in pro-inflammatory cytokines such as $\text{TNF-}\alpha$ that will increase the host response to periodontal pathogens and consequently, the host tissue itself.

Given the inconveniences and detrimental life-changing effects this disease brings towards its patients, more emphasis in the research to elucidate the mechanisms and treatments of periodontal disease should be given. Genetic testing at an early age could help patients with their choice of

lifestyle. If done appropriately, genetic testing can also help patients avoid potential triggers of periodontal disease in life, which we discuss in this report.

Orthodontic Treatment Triggering Localized Bone Loss

Here we describe a case of a female patient who presented with generalized mandibular bone loss in her late 20s. The patient had bilateral maxillary canines slightly overlapping lateral incisors creating crowding of the four teeth after the eruption of permanent teeth and therefore received orthodontic treatment at age 16 when she was in a Taiwanese high school. Prior to the orthodontic treatment, the patient had no signs of periodontal disease; however, her father began to manifest signs of bone loss during his college years, suggesting a familial susceptibility.

The first trigger

The patient had orthodontic brackets for 16 months and during the course of the treatment, she reported to her orthodontist that she was aware that her gum lines had receded slightly on her right maxillary central incisor and the mandibular anterior teeth. Her orthodontist confirmed her observation but did not mention how he would proceed on managing the receding gingiva. He simply stated that there is nothing he can do and "gums do not grow back, once they are lost, they are gone forever." Disheartened, the patient tried to move past the depressing news. After debonding of orthodontic brackets, the patient was instructed to wear upper and lower arch removable retainers during sleep. She was never given an option of placing a lingual bar on her mandibular anterior teeth.

The patient noticed that after debonding and a period of time wearing her lower retainer, her mandibular left canine became more tipped towards the lingual. In addition, whenever she worn her mandibular retainer, pain and strain on teeth occurred in her entire arch, with the discomfort exaggerated on the left mandibular canine. She reported this to her orthodontist; however, relieving the wires that rested on the left mandibular canine did not show any improvement. The patient still had discomfort and eventually discontinued the use of retainers after 5 years. Over the course of 10 years after debonding, the patient noticed the slow

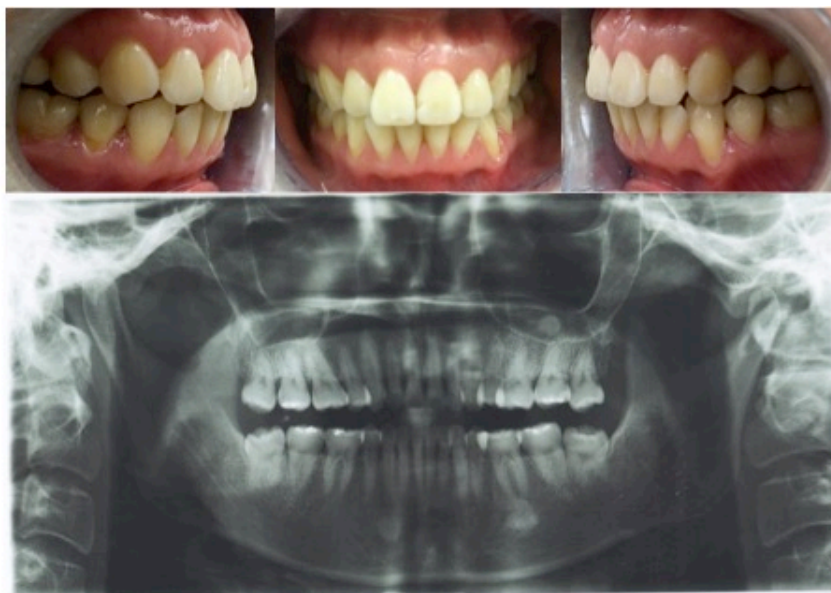

Figure 2. Intraoral photographs and panoramic radiograph. It is evident that the patient has bone loss from canine to canine in the mandible and mild bone loss on the right maxillary central incisor and left mandibular canine on the intraoral photographs. In the panoramic radiograph, evident bone loss is seen at both maxillary and mandibular anterior teeth.

progression of gingival recession on the mandibular anterior teeth.

The second trigger: stress

At age 28, the patient began professional school and during the intense and stressful first year of courses, she noticed that her entire mandibular arch had gingival recession in addition to progressive attachment loss on the mandibular canines. At age 29 and second year of studies, she decided that she would be seeking periodontal treatment.

Family history

The patient's father, now 59 years old, had begun developing periodontal problems since college. His father (the patient's grandfather) had complete dentures by age 65. He got his teeth

cleaned for the first time in college, at age 20, and reported "after the hygienist got rid of my calculus, I felt that my teeth became loose and a little wobbly." Later in graduate school, at age 22, he picked up the habit of smoking because of the stress to which he was subjected. He reports that he does not remember if he began to notice bone loss around his teeth but at age of 35 during a visit to a dental office, he was diagnosed with moderate periodontitis. The patient's father kept his condition under control and has not lost teeth since his diagnosis. The patient's mother does not have periodontal disease.

Discussion

This case illustrates periodontal bone loss triggered by or-

thodontic movement and/or stress aggregating in the same family. Periodontitis aggregates in this family (Figure 1) in an apparent autosomal dominant mode of inheritance since the father (and possibly the grandfather) potentially had periodontitis and the patient, a potential third generation case, also manifests signs of bone and attachment loss.

Previous studies [3,4] have suggested familial aggregation in early onset periodontitis. It was also suggested that autosomal recessive genes and environmental factors were responsible for the transmission of the disease in early onset periodontitis due to the shared genes among biologic family and possible saliva transmission of bacteria such as *Aggregatibacter actinomycetemcomitans* [3]. A report of monozygotic twins [4] strongly suggested that adult chronic periodontitis is influenced by genetic and environment factors, although there is the notion that early family environment plays less of a significant role [5]. Recent studies have indicated that the Interleukin-1 (IL1) gene serves as an important regulator for the expression of periodontitis. Both the T allele of rs17561 of IL1- α and IL1- β β β β rs1143634 T allele are positively associated with periodontitis [6]. Other polymorphisms of IL1- α were also shown to have an association with moderate to severe periodontitis across different ethnicities [7].

This case report substantiates that periodontal disease is of

multifactorial inheritance. Since one of the risks of orthodontic treatment is the development of periodontal loss, it is not possible to determine exactly whether it was the treatment or the genetic factor that caused bone loss. A synergistic effect of the two factors could be a possible factor that contributed to the onset of the periodontal problems the patient presented here had. However, it is worth noticing that there was only localized bone or attachment loss of buccal of the left mandibular canine after debonding and no signs of generalized attachment loss in the mandible or maxilla. Between debonding and entering professional school, a 10-year gap, the patient reported remembering gradual loss of attachment on the posterior mandibular teeth.

During the first year in professional school, the patient began to notice rapid attachment loss on the mandibular incisors showing cementum on the buccal aspect of the teeth and the anterior teeth became sensitive to cold where the cementum-enamel junction was exposed (Figure 2). These signs and symptoms all indicate that the environment factor (i.e., orthodontic treatment in adolescence and stressful life) determined the course of the disease in addition to the possible variable IL1 gene expression of the patient.

References

1. Newman MG, Takei HH, Klokkevold PR, Carranza FA. (2016). Carranza's Clinical Periodontology.
2. Dental implants in the periodontal patient. Greenstein G, Cavallaro J Jr, Tarnow D. Dent Clin North Am. 2010 Jan;54(1):113-28. doi: 10.1016/j.cden.2009.08.008. Review. PMID:20103475
3. Familial aggregation of periodontal indices. Beaty TH, Colyer CR, Chang YC, Liang KY, Graybeal JC, Muhammad NK, Levin LS. J Dent Res. 1993 Feb;72(2):544-51. PMID:8423252
4. Chronic periodontitis with familial aggregation and discordant identical twins. Grech SC. Dentistry 3000 2015; 3(1). Doi: 10.5195/d3000.2015.30
5. Genetic and inheritance considerations in periodontal disease. Michalowicz BS. Curr Opin Periodontol. 1993:11-7. Review. PMID:8401833
6. Association between IL-1 α rs17561 and IL-1 β rs1143634 polymorphisms and periodontitis: a meta-analysis. Yin WT, Pan YP, Lin L. Genet Mol Res. 2016 Feb 5;15(1). doi: 10.4238/gmr.15017325. PMID:26909953
7. Association of interleukin-1 gene variations with moderate to severe chronic periodontitis in multiple ethnicities. Wu X, Offenbacher S, López NJ, Chen D, Wang HY, Rogus J, Zhou J, Beck J, Jiang S, Bao X, Wilkins L, Doucette-Stamm L, Kornman K. J Periodontal Res. 2015 Feb;50(1):52-61. doi: 10.1111/jre.12181. Epub 2014 Apr 2. PMID:24690098