

A Randomized Control Trial for Comparative Evaluation of 3-D Versus 2-D Miniplates For Internal Fixation of Mandibular Fractures

Sanjay Kumar, Nageshwar Iyer, Mansi Jain

Abstract

Fractures of the mandible are a common facial injury. For restoration of normal jaw structure and function, proper bony healing is important; thus, stable plate osteosynthesis has become an indispensable component of cranio-maxillofacial surgery.

AIM: This study aims to evaluate the efficacy of 3D versus 2D mini bone plates used for internal fixation of mandibular fractures.

MATERIALS AND METHODS: A prospective randomized control trial was conducted on 20 patients with mandibular fractures in the symphysis and parasymphysis regions. In group 1, 3-D miniplates were used with a single, rectangular, 4-holed titanium plate with 4 screws and in group 2, 2-D miniplates were used with two 4-holed titanium plates fixed with 8 screws. Time taken for fixation and operator comfort was analysed using the Chi square test, whereas trismus and pain were analysed using Anova.

RESULTS:

1. The difference for mean time taken for fixation was statistically highly significant ($P < 0.01$) between 3-D (33.1 minutes) and 2-D plate (44.7 minutes).
2. Fixation of 2-D plates was found more comfortable.
3. Swelling in both the groups was generally comparable and lasted for about 1 week.
4. Mouth opening in patients of both the groups showed a gradual recovery till 1 month after surgery, after which it stabilized.

CONCLUSION: 3-D miniplates were more economical, with less operative time required and with better performance over 2-D miniplates. However there was difficulty in their adaption and they were inappropriate when the fracture line was very close to the mental foramen.

KEYWORDS: Titanium 3-D Miniplates; Titanium 2-D Miniplates; Internal Fixation; Mandibular Fractures; facial injuries

Citation: Kumar, S et al. (2022) A Randomized Control Trial for Comparative Evaluation of 3-D Versus 2-D Miniplates For Internal Fixation of Mandibular Fractures Dentistry 3000. 1:a001 doi:10.5195/d3000.2022.348
Received: May 11, 2022
Accepted: July 5, 2022
Published: August 12, 2022
Copyright: ©2022 Kumar, S et al. This is an open access article licensed under a Creative Commons Attribution Work 4.0 United States License.
Email: mansijainsoni@gmail.com

Introduction

In this age of technological progress, there has been a notable increase in trauma including the maxillofacial region. The face, being the most admired point in one's body, any defacement due to trauma would greatly affect a person both physically and psychologically. Hence, any injury

to maxillofacial region needs urgent and skilled management [1].

Fractures of the mandible are more common than middle-third facial injuries and are the second most common after nasal fractures [2]. A primary objective in the management of fractures in the maxillofacial region is the restoration of normal jaw

structure and function which should be accomplished expeditiously and with least patient discomfort. Union of the fracture segments will occur in the absence of gross mobility; hence, stability of the segments is key for proper hard and soft tissue healing in the injured area. Therefore, the fracture site must be stabilized in

order to guide the process toward normal bony healing. Hippocrates (460-375 B.C.) was the first to mention bandages as a method to immobilize fractures of jaw using leather straps with a paste to adhere to the skin to apply direct traction [3]. Schede (1888) is credited with first use of bone plates and secured with four screws [4]. Champy M et. al. (1978) introduced a miniplate system to treat midface fracture [2]. Bone plates are placed according to the Champy's line of osteosynthesis perpendicular to the fracture line [5]. Stable plate osteosynthesis has become an indispensable component of cranio-maxillofacial surgery in the treatment of fractures and in osteotomies of the facial bones. Farmand Min (1990) developed a new miniplate system made of Titanium known as three dimensional plating systems (3-D) that takes the advantages of bio-geometry to provide stable fixation [6]. The basic concept of three dimensional fixations is the geometrically closed quadrangular plate to create stability in all three dimensions [2].

Hence this study was conducted to compare the efficacy of 3-D versus 2-D bone plates used for internal fixation of mandibular fractures.

Material and Methods

A prospective randomized control trial was conducted after approval of institution ethical committee IEC project number 1491 and carried out in accordance with *The Code of Ethics*

of the World Medical Association (*Declaration of Helsinki, 2013*) on 20 subjects, serially selected for the study from the out-patient department of Oral and Maxillofacial Surgery. All patients with fairly good general health (ASA- I & II), without any contraindication for surgery with fracture between the mental foramina in anterior region of mandible, with or without other associated fractures and indicated for internal rigid fixation were included in study.

Patients with neurological damage from head injury, with pre-existing motor paralytic disease, grossly displaced or comminuted fractures, fracture lines passing through or very close to the mental foramina and edentulous patients in whom occlusion was not assessable were excluded from the study.

Preoperative treatment

Preoperative Erich's arch bar, maxillo-mandibular fixation screw or Ivy eyelet loop wiring as indicated were placed with 26 gauge soft stainless steel wire on both the arches to achieve the pre morbid occlusion.

For Group 1:

1. Titanium 3-D miniplates, 2 mm system
 - 2 x 2 holes
2. Titanium screws
 - 2 x 6 mm
 - 2 x 8 mm
 - 2 x 10 mm

For Group 2:

3. Titanium 2-D miniplates, 2 mm system and 2.5 mm system
 - 4 holes with extended bar
4. Titanium screws
 - 2 x 6 mm
 - 2 x 8 mm
 - 2 x 10 mm
 - 2.5 x 8 mm
 - 2.5 x 10 mm

Surgical technique

All the patients were operated intra orally except one, who had a lacerated wound near the mental region. De-gloving incisions in symphysis or parasymphysis region were made.

Reduction of fracture

Fracture reduction was done to achieve occlusion with the help of maxillo-mandibular fixation using arch bar, IMF screw or eyelet wiring. Reduction under direct supervision using two pronged reduction clamps were done in cases where the arch bar reduction could not be done.

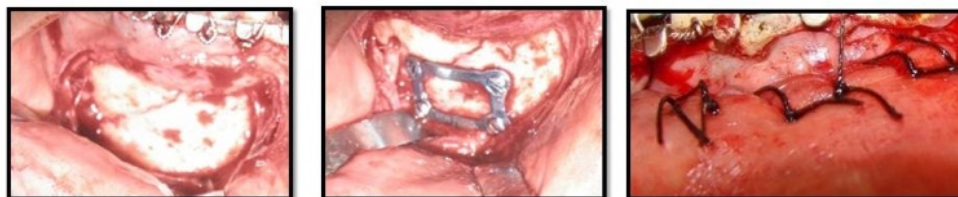Adaption & fixation of plate

After fracture reduction, fixation was done using a single three dimensional plate in group 1 (3-D) patients and

two 4- holed with extended bar in group 2 (2-D) patients.

Group 1 - Titanium 3-D 2 x 2 hole bone plate was adapted to confirm to the bone contour and lie passive against the bone surfaces. The horizontal crossbars were positioned perpendicular to the fracture line and vertical struts were placed parallel to fracture line. In oblique fracture, the plates were placed parallel to the lower border of mandible and in parasymphyseal fractures, the upper crossbar was placed in the subapical position. The drilling was performed through the hole in the plate perpendicular to the bone surface. The first screw was inserted in the drilled hole using a 2 mm screw holding device and the second hole was placed diagonally. Layer wise suturing of the soft tissue was done and pre-operative maxillomandibular fixation was removed after the completion of the procedure (Fig 1, 2).

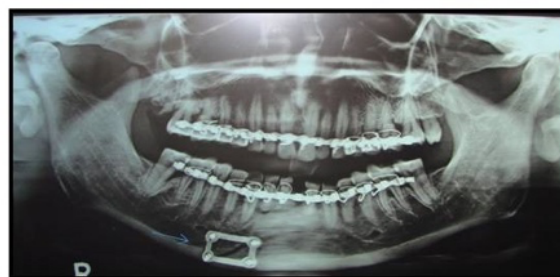INTRA-OPERATIVE



FRACTURE SITE EXPOSED

3-D MINI PLATES FIXATION

SUTURES PLACED

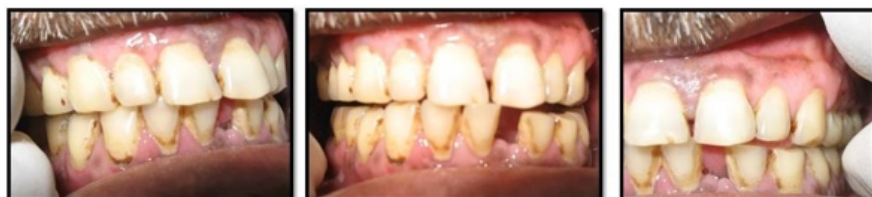

ORTHOPANTOMOGRAM SHOWING 3-D MINIPLATE FIXED AT FRACTURE SITE

Figure 2. Case 1 – Placement of 3-D plates

Group 2- Bone plates were positioned perpendicular to the fracture line according to the Champy’s line of osteosynthesis. The plate was adapted according to the contour of bone and held firmly with hand instruments. Drilling was performed through the hole in the plate

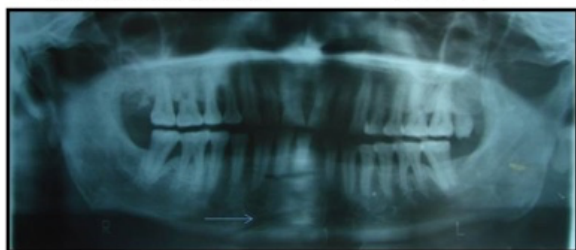
perpendicular to the bone surface. Two parallel plates were used to neutralize torsional forces in the symphysis region between the two mental foramina. The lower plate was fixed first, followed by the sub-apical plate (Fig 3, 4).



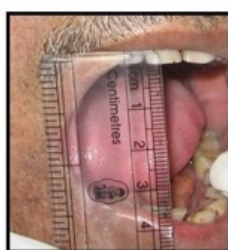RIGHT LATERAL VIEW

FRONTAL

LEFT LATERAL VIEW



ORTHOPANTOMOGRAM SHOWING FRACTURE OF RIGHT PARASYMPHYSIS



MOUTH OPENING

Figure 1. Case 1 – Preoperative view showing right parasymphysis fracture

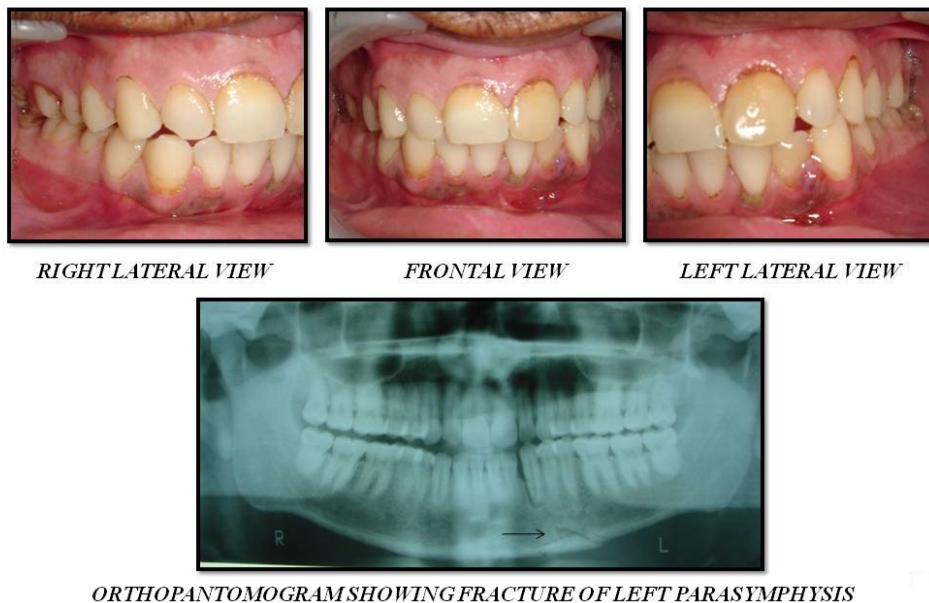


Figure 3. Case 2 – Preoperative view showing left parasymphysis fracture

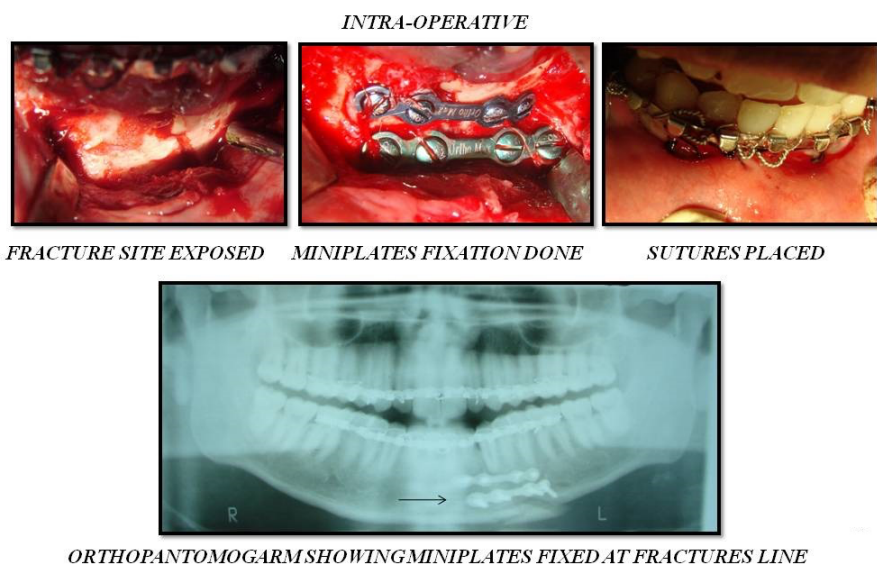


Figure 4. Case 2 – Placement of two 2-D plates

Post-operative follow up

Clinical and radiological follow up for 3 months postoperatively regarding the restoration of function, occlusion, stability of system used, ease of application and cost of treatment, incidence of operative & post-operative complication i.e. infection,

dehiscence of wound, loosening of screw, disturbance in occlusion, nonunion and malunion was done.

Statistical Analysis

Time taken for fixation and operator comfort was analysed using the Chi

square test. Trismus and pain were analysed using Anova.

Results

All the patients were male with a mean age of 28 years (range 19 to 45 years). Fractures on the right side predominated in the ratio of 3:2. All the fractures were due to road traffic accidents.

Following were the findings of the study:

- 1) Mean time taken for fixation of 3-D plate was 33.1 minutes (ranging from 25 to 37 minutes); that for 2-D plate was 44.7 minutes (ranging from 40 to 50 minutes). The difference was highly significant ($P < 0.01$). (Table 1)
- 2) Fixation of 2-D plate was found more comfortable by the operator. The difference was highly significant ($P < 0.01$). (Table 2)
- 3) Swelling in both the groups was generally comparable and lasted for about 1 week. (Table 3)
- 4) Neurosensory deficit associated with mental nerve was found in 3 patients in group 2 (2-D plate) which lasted for a longer duration (1 month) as compared to only in 1 patient in group 1 (3-D plate) which lasted for 2 weeks. (Table 4)

5) There was no difference between the two groups in terms of reduction of masticatory efficiency. (Table 5)

6) Mouth opening in patients of both the groups showed a gradual recovery during the first month after which it stabilized. (Table 6)

7) There was a gradual decrease in pain in patients of both groups. None of the patients complained of pain after 1 week. (Table 7)

Discussion

Injuries to the face can lead to devastating esthetic and functional sequelae. Despite improved technology and fixation techniques for mandibular fractures, its management still remains challenging [7]. The anatomy of the mandible and vector of forces exerted by the masseter and temporalis muscles make symphysis/parasymphysis fractures exceedingly difficult. These vector forces tend to displace the segments of the mandible at the site of fracture. Besides, the torsional

forces, there are overlapping tensile and compressive loads in both the directions [1].

Furthermore, the intra-operative and post-operative periods have become more comfortable for the surgeon as well as the patient. The 3D miniplates hold the fracture fragments rigidly by resisting the shearing, bending and torsional forces. Farmand (1995) stated that a geometrically closed quadrangular plate secured with bone screws creates stability in all three dimensions. The stability is gained over a defined surface area and is achieved by its configuration, not by thickness or length. The large free areas between the plate arms and minimal dissection utilized permit good blood supply to the bone [6]. As both symphysis and parasymphysis fractures are under higher torsional strain than other areas of the mandible; 3D plates in this area provide superior stability [2].

In the present study, patients in group 1 had a mean age 32.8 years, and in group 2 a mean age of 23.2 years. This agrees with Sawhney CP

and Ahuja RB, who observed that 75% of the cases were in the 16 – 45 year age group [8]. Erdmann et al reported that road traffic accidents to be a common etiology for mandibular fractures [9]. Lida S, Kogo M et. al. (2001) in a retrospective analysis of 1,502 patients with facial fractures reported that male: female ratio was 2.8:1 with the largest subgroup being patients between 10 - 29 years of age [10]. Abosadegh Maher et al. reported that the largest group was in the age group of 20 – 39 years with a male: female ratio of 5:1 [11].

In Group 1 patients, the total time taken for the procedure from the placement of incision till the completion of closure was in the range of 25–37 minutes (mean 33.1 minutes) whereas in group 2, it was in the range of 40 to 50 minutes(mean 44.7 minutes) which was a highly significant difference (P < 0.01). (Table 1) It was in accordance with those who reported mean intraoperative times of 54.8 min for 2D miniplates and 40.6 for 3D miniplates [12].

Table 1: Mean time taken for fixation in minutes

Group	Time taken		
	Range (min)	Mean (min)	S.D (min)
I (3D – Plate)	25 - 37	33.1	3.41
II (2D – Plate)	40 – 50	44.7	3.52
Total	25 - 50	38.9	6.84

*P < 0.01 Highly Significant

Operator comfort for the placement of miniplates was judged as good, moderate or bad. It was observed that in group 1 it was moderate for 6

patient and good for 4 patients. In group 2 it was found to be good for all the 10 patients (Table 2). The difference was highly significant (P <

0.01). Hence, this shows that placement of conventional miniplates is easier as compared to 3-D plate.

Table 2: Operator’s Comfort

Group	Total (No. of pts)	Good (No. of pts)	Moderate (No. of pts.)	Bad (No. of pts.)
I(3D- Plate)	10	4	6	0
II(2D- Plate)	10	10	0	0
Total	20	14	6	0

*P < 0.01 Highly Significant

Swelling was graded in all cases included in the study as none, mild, moderate or severe. It was observed that swelling reduced progressively with time. Immediately postop, group 1 swelling was graded as mild in 9 patients and moderate in 1 patient.

After 1 week, mild swelling was present in 4 patients. After follow up of two weeks none of patients reported with swelling (Table 3). In group 2 swelling postoperatively was graded as mild in 8 patients and moderate in 2 patients. After 2 weeks

1 patient reported with swelling. On regular follow up none of the patient reported with swelling (Table 3). Neither method of fixation induces much swelling after placement.

Table 3: Swelling in Group

Group	Swelling	No: of Patients						
		Pre-Tt	Immd Post-Op.	1wk	2wk	1mon.	2 mon.	3mon
I (3D – Plate)	Mild	9	9	4	0	0	0	0
	Moderate	1	1	0	0	0	0	0
	Severe	0	0	0	0	0	0	0
	Total	10	10	4	0	0	0	0
II (2D– Plate)	Mild	8	8	1	1	0	0	0
	Moderate	2	2	0	0	0	0	0

	Severe	0	0	0	0	0	0	0
	Total	10	10	1	1	0	0	0
Grand Total		20	20	5	1	0	0	0

Sensory changes were also observed throughout the period of study as paresthesia in the region of miniplates fixation. In group 1, 10% patient reported with neurosensory deficit post-operatively which

recovered fully after 2 weeks follow up. In group 2, 30% reported with post-operative neurosensory deficit. After follow up of 1 month, recovery was complete in all the patients. None of the patients reported with

permanent neurosensory deficit (Table 4). [Nilima J. Budhraj](#) et al (2018), also reported that no patients treated with three dimensional miniplates had neurosensory deficit [13].

Table 4: Number of patients with Neurosensory Deficit

Group	Total No: of Patients	No. of Patients with Neurosensory Deficit						
		Pre t/t	Immd Post-Op.	1wk	2wk	1mon	2mon	3mon
I (3D-Plate)	10	1	1	1	1	0	0	0
II (2D-Plate)	10	3	3	2	1	1	0	0
Total	20	4	4	4	2	1	0	0

Masticatory efficiency was observed in all the patients throughout the study. Patients of both groups were kept on soft diet for a period of two weeks. After follow up of 1 month all the patients were able to chew on medium hard food and after 2 months all the patients in both groups were able to chew hard food (Table 5).

Table 5: Masticatory Efficiency

Group	Masticatory Efficiency Score	No. of pts						
		Pre t/t	1 day post t/t	1wk post t/t	2weeks post t/t	1month post t/t	2month post t/t	3month post t/t
I (3D– Plate)	0	10	0	0	0	0	0	0
	1	0	10	10	4	0	0	0
	2	0	0	0	6	10	0	0
	3	0	0	0	0	0	10	10
II (2D– Plate)	0	10	0	0	0	0	0	0
	1	0	10	10	6	0	0	0
	2	0	0	0	4	10	0	0
	3	0	0	0	0	0	10	10

*Key: 0 = Unable to chew
 1 = Able to chew soft food
 2 = Able to chew medium hard food
 3 = Able to chew hard food

Inter-incisal mouth opening also increased progressively with passage of time. Mean mouth opening pre-treatment was 20.1 mm in group 1

and 19.5 mm in group 2, which increased to 23.1 mm and 20.2 mm for group 1 and group 2 respectively immediately postoperatively. No

statistically significant difference (P > 0.05) was found between the two groups at 3 months post operatively (Table 6).

Table 6: Mean Trismus Index (Inter incisal opening in mm)

Group	Total No: of Patients	Mean Trismus Index (mm)						
		Pre t/t	Immediately post t/t	1wk	2wk	1mon	2mon	3mon
I (3D– Plate)	10	20.1	23.1	25.9	29.4	36.5	37.2	37.4
II (2D– Plate)	10	19.5	20.2	23.6	26.6	33.9	36.1	36.8
Total	20	19.8	21.65	24.75	28	35.2	36.6	37.1

*P > 0.05

Pain was assessed in all the patients on a Visual Analogue Scale (VAS) of 0-100. Pretreatment mean value for

group 1 was 78 and for group 2 was 85 (Table 7). This gradually reduced to 0 by the end of two weeks.

Statistical analysis (ANOVA) was not significant ($P > 0.05$) between the groups.

Table 7: Pain on Visual Analogue Scale

Group	Total No: of Patients	Visual Analogue Scale						
		Pre t/t	1 day post t/t	1week post t/t	2weeks post t/t	1month post t/t	2month post t/t	3month post t/t
I (3D– Plate)	10	78	37	5	0	0	0	0
II (2D– Plate)	10	85	31	6.5	0	0	0	0
Total	20	81.5	34	5.75	0	0	0	0

* $P > 0.01$ - not Significant

Other complications studied were infection, exposure of plate, fracture of the hardware, and any other complication associated with placement of miniplates. None of the patients reported with infection post-operatively. 1 patient in group 2 reported with wound dehiscence and exposure of the root of right mandibular lateral incisor. None of the patients in either groups reported with fracture or exposure of the hardware or any other complication.

It was concluded from the present study that 3D plates were easy and simple to use except in cases involving the mental nerve [14]. Presence of connecting arms made the plate placement comfortable without displacement. The quadrangular geometry of plate assures a 3D stability at the fracture site and offers good resistance against torque forces, thereby avoiding the need for

maxillomandibular fixation. Further, there was no major postoperative complications such as nonunion or hardware failure.

Conclusion

3-D miniplates have the advantage of low cost and less operative time required. Further no fracture or exposure of hardware was seen. However they were difficult to adapt and inappropriate when the fracture line is very close to the mental foramen. On the other hand 2-D miniplates were easier to adapt, but were harder to place, time consuming, with higher cost.

Clinical Significance

Being more economical, requiring less intraoperative time and with equally good postoperative results, 3-D miniplates are preferable over 2-D miniplates.

Ethical Statement

The study was approved by the institutional ethical committee.

Conflict of Interest

There is no "Conflict of interest" between the authors.

References

1. Comparison of 2 mm single locking miniplates versus 2 mm two non-locking miniplates in symphysis and parasymphysis fracture of mandible. Vashistha A, Singh M, Chaudhary M, Agarwal N, Kaur G. *J Oral Biol Craniofac Res.* 2017 Jan-Apr; 7(1):42-48. DOI: [10.1016/j.jobcr.2016.01.001](https://doi.org/10.1016/j.jobcr.2016.01.001), PMID: [PMC5343153](https://pubmed.ncbi.nlm.nih.gov/27111113/)
2. Three-Dimensional Miniplate: For the Management of Mandibular Parasymphysis Fractures. Mohd YQ, Reddy S, Sinha R, Agarwal A, Fatima U, Abidullah M. *Ann Maxillofac*

- Surg. 2019; 9(2):333-339.
DOI:[10.4103/ams.ams.172.17](https://doi.org/10.4103/ams.ams.172.17)
PMID: [31909011](https://pubmed.ncbi.nlm.nih.gov/31909011/)
3. Advancements in Management of Mandibular Fractures. Kanwaldeep Singh Soodan and Pratiksha Priyadarshni. Acta Scientific Dental Sciences.2018; 2.5: 29-31.
 4. Booth PW, Stephen AS, Harisamen JE.(1999) Maxillofacial surgery.Vol-1, Edinburgh: Churchill Livingstone.
 5. Single Miniplate Fixation for Mandibular Symphysis and Parasymphysis Fracture as a Viable Alternative to Conventional Plating Based on Champy's Principles: A Prospective Comparative Clinical Study. Raut R, Keerthi R, Vaibhav N, Ghosh A, Kamath Kateel S. J Maxillofac Oral Surg. 2017;16(1):113-117.
DOI: [10.1007/s12663-016-0919-1](https://doi.org/10.1007/s12663-016-0919-1), PMID: 28286395
 6. A Comparative Study of 3-Dimensional Titanium Versus 2-Dimensional Titanium Miniplates for Open Reduction and Fixation of Mandibular Parasymphysis Fracture. Yogesh Mittal, K. George Varghese, S. Mohan, N. Jayakumar, and Somil Chhag. J Maxillofac Oral Surg. 2016 Mar; 15(1): 93–98.
DOI: [10.1007/s12663-015-0780-7](https://doi.org/10.1007/s12663-015-0780-7), PMID: [26929559](https://pubmed.ncbi.nlm.nih.gov/26929559/)
 7. Mandible Fractures. Pickrell BB, Serebrakian AT, Maricevich RS. Semin Plast Surg. 2017 May;31(2):100-107.
DOI: [10.1055/s-0037-1601374](https://doi.org/10.1055/s-0037-1601374), PMID: 28496390
 8. Faciomaxillary fractures in North India a statistical analysis and review of literature. Sawhney CP and Ahuja RB. Br J Oral Maxillofac Surg 1988;26:430-4.
DOI: 10.1016/0266-4356(88)90097-6, PMID: 3191093.
 9. A Retrospective Analysis of Facial Fracture Etiologies, Annals of Plastic Surgery. Erdmann Detlev, Follmar Keith E., DeBriijn Marlieke, Bruno Anthony D., Jung Sin-Ho, Edelman David, Mukundan Srinivasan MD, Marcus Jeffrey R. April 2008 ; 60(4):398-403.
DOI: [10.1097/SAP.0b013e318133a87b](https://doi.org/10.1097/SAP.0b013e318133a87b), PMID: 18362568
 10. Retrospective analysis of 1502 patients with facial fractures. Lida S, Kogo M, Sugiura T, Mima T, Matsayu T. Int J Oral Maxillofac Surg 2001;30:286-90.
DOI: 10.1054/ijom.2001.0056, PMID: 11518349.
 11. Epidemiology and incidence of traumatic head injury associated with maxillofacial fractures: A global perspective. Abosadegh Maher M, Rahman Shaifulizan A. B. Journal of international oral health. 2018; 10 :(2):63-70.
DOI: [10.1111/j.1365-2842.2007.01799.x](https://doi.org/10.1111/j.1365-2842.2007.01799.x), PMID: 18034671
 12. A Comparative Evaluation of 2.0mm Two-Dimensional Miniplates Versus 2.0mm Three-Dimensional Miniplates in Mandibular Fractures. Godvine Sarepally, Swetcha Seethamsetty, Tanveer Karpe, Fazil A Nasyam, Umayra Fatima, Raia Fatema: Cureus. 2022 Jan; 14(1): e21325.
DOI: [10.7759/cureus.21325](https://doi.org/10.7759/cureus.21325), PMID: [35186584](https://pubmed.ncbi.nlm.nih.gov/35186584/)
 13. Three-dimensional Locking Plate and Conventional Miniplates in the Treatment of Mandibular Anterior Fractures. Nilima J. Budhraj, Ramakrishna S. Shenoj, Samprati J. Badjate, Kshitij O. Bang, Pranav D. Ingole, Vrinda S. Kolte. Ann Maxillofac Surg. 2018 Jan-Jun; 8(1): 73–77.
DOI: [10.4103/ams.ams.175.17](https://doi.org/10.4103/ams.ams.175.17), PMID: [29963428](https://pubmed.ncbi.nlm.nih.gov/29963428/)
 14. Comparison of 3-dimensional and standard miniplate fixation in the management of mandibular fractures. Manoj Kumar Jain, K S Manjunath, B K Bhagwan, Dipit K Shah. J Oral Maxillofac Surg. 2010 Jul; 68(7):1568-72.
DOI: [10.1016/j.joms.2009.07.083](https://doi.org/10.1016/j.joms.2009.07.083), PMID: 20417012