

Selective Root Retreatment: A Randomized Clinical Trial

Mohamed Nagy¹, Ahmed Ghobashy²

¹Associate Professor of Endodontics, Faculty of Dentistry, Ain Shams University, Cairo, Egypt

²Associate Professor of Endodontics, Department of Conservative Dentistry, Faculty of Dentistry, Misr International University, Cairo, Egypt

Abstract

Objectives: Post-treatment apical periodontitis is an inflammatory disorder of peri-radicular tissues caused by either persistent or secondary intra-radicular infection. The present study compared the prognosis of cases treated with the “selective root retreatment” concept to the traditional retreatment approach.

Material and Methods: Forty patients complaining of failed root canal treatment having a periapical lesion in one root were selected. The cases were randomly divided into two groups; group (S): selective root canal retreatment in which only the affected root was retreated and group (T): traditional root canal retreatment in which all canals were retreated. The peri-radicular condition was evaluated radiographically using the Periapical Index (PAI) for one year. The chi-square test statistical tests analyzed the outcome data.

Results: At the baseline examination, there was no significant difference between the two groups regarding the patients’ baseline mean periapical indices. After one year, we found that the mean periapical index declined without a significant difference between the two groups.

Conclusions: The present study points to selective root retreatment as a successful “minimally invasive alternative” in cases of an independently diseased root. The remaining treated roots can be retained without intervention provided that they are confirmed: “healthy”.

Clinical Relevance: Selective root retreatment is a promising conservative option in the treatment of failed endodontic cases with periapical pathosis related to an individual root.

Citation: Nagy & Ghobashy (2022). Selective Root Retreatment: A Randomized Clinical Trial Dentistry 3000. 1:a001 doi:10.5195/d3000.2022.339
Received: April 24, 2022
Accepted: June 23, 2022
Published: 13 July, 2022
Copyright: ©2022 Nagy & Ghobashy. This is an open access article licensed under a Creative Commons Attribution Work 4.0 United States License.
Email: mohamed.nagy@dent.asu.edu.eg

INTRODUCTION

Post-treatment apical periodontitis is an inflammatory disorder of peri-radicular tissues caused by either persistent or secondary intra-radicular infection [1, 2]. Persistent infections are caused by microorganisms that persisted and survived after root canal obturation. Secondary infections are usually caused by microorganisms introduced in the canal via coronal or apical leakage in obturated root canals. These microorganisms usually remain in a biofilm state [3]. The decision-making in such cases is influenced by the endodontist’s ability to identify and eradicate the underlying etiology responsible for

the established disease. Management of such cases includes nonsurgical retreatment, surgical treatment, or a combination of both procedures [4].

Conventionally, nonsurgical retreatment has been believed to be an “all or none” treatment approach [5] in which the endodontist has to remove all restorations from the tooth and remove the obturation materials from all the canals in order to perform thorough disinfection of the entire root canal system. Such an approach involves unwanted removal of dentin and, consequently, more weakening of the tooth structure, besides the increased possibility of potential

iatrogenic errors [6], which might endanger the outcome of the case.

Nowadays, all operations in the medical field are aimed basically at the conservation of the human body [7]. In Endodontics, the integrity of the tooth structure is a crucial factor that influences the case prognosis as it is directly related to the functional requirements of the tooth after restoration [8, 9].

In the past, treatment planning has been limited by two-dimensional radiographic imaging [10–12]. Nowadays, with the introduction of Cone-beam computed tomographic (CBCT) imaging, it is possible to detect

initial apical periodontitis before significant cortical bone demineralization [13]; consequently, the presence of periapical pathosis can be more precisely detected via CBCT compared with conventional two-dimensional radiographic imaging techniques [14]. This alternative concept allows the endodontist to formulate clinical treatment decisions with respect to the presence of periapical pathosis related to individual roots rather than the tooth as a whole; therefore, the term “selective root retreatment” is advocated [15], i.e., to retreat the diseased root only while retaining the remaining treated roots without intervention provided that they are confirmed, “healthy.”

Up to date, the literature is lacking the clinical outcome studies dealing with the prognosis of cases treated with the “selective root retreatment” concept, so the aim of this study was to compare the prognosis of such cases in comparison to the traditional retreatment approach.

MATERIALS AND METHODS

This double-blind, multi-center, with a parallel design randomized controlled trial was registered on www.clinicaltrials.gov (ClinicalTrials.gov ID: NCT04737863).

The study protocol was approved by FDASU-REC (Faculty of Dentistry, Ain Shams University-Research Ethical Committee) institutional review board, and the study was performed in accordance with all applicable laws

and regulations, including the Declaration of Helsinki.

Power calculation was performed using G*Power 3.1 software [16] (Heinrich Heine University, Dusseldorf, Germany). The calculation indicated that the sample size for each group should be a minimum of 15 cases

Forty study subjects were recruited from 2 private endodontic clinics between March 2019 and March 2021 complaining of failed root canal treatment. Patients were selected according to the inclusion and exclusion criteria.

Inclusion criteria

- Patients who had an intact restoration at follow-up;
- Teeth having a baseline periapical lesion (PAI score ≥ 3) in one root.

Exclusion criteria

- Patients who refused to undergo radiographic follow-up;
- Pregnant females;
- Patients suffered from a systemic disease;
- Teeth having a periapical lesion in two or more roots;
- Teeth with lesions connected to adjacent teeth;
- Teeth with root fractures or perforations;
- Teeth with lesion communicating with the alveolar crest.

All teeth included in the analysis were selected by two blinded, independent evaluators based on the preoperative parallel periapical radiograph. All participants signed a written consent after an oral explanation of the aim of

the study, the procedures, benefits, and the potential risks. The treatment options presented to the patient included traditional nonsurgical retreatment (removal of all restorative materials), or selective root canal retreatment (isolating the necessary procedures to the affected root), or extraction.

Two endodontists participated as investigators. The investigators ensured that subject names and data were kept confidential. The clinical examination involved periodontal pocket depths measurement, mobility testing, the presence or absence of swelling, percussion, and palpation. CBCT evaluation was done for each study tooth before the procedure and at the 12-month follow-up visit. Standardized parallel periapical radiographs were taken preoperative, postoperative, then every three months up to one year of follow-up.

The cases were randomly divided into two groups; group (S): selective root canal retreatment and group (T): traditional root canal retreatment. Randomization was done using <http://www.random.org>.

Group (S): For each case, profound anesthesia was administered, dental dam isolation was performed. Under a dental operating microscope (OPMI PICO; Carl Zeiss, Gottingen, Germany), the subject tooth was accessed using a suitable-sized round diamond stone under copious water irrigation. The affected root canal was identified. The old root canal filling was removed using hand and rotary instruments aided solvents. Working length was

re-established electronically and confirmed radiographically. A patent reproducible glide path was created to size #20/.02 and enlarged using ProTaper Next (Dentsply Maillefer) X1, X2, and X3 at a rotational speed of 300 rpm and 200 g/cm torque. Each file was used with a brushing motion. An irrigation protocol consisting of 2.6% NaOCl in conjunction with ultrasonic activation was used for canal disinfection. The canal was dried using paper points and obturated using the continuous wave condensation technique. The access was restored, and a final postoperative radiograph was taken. Postoperative instructions were provided, and the patient was left for follow-up for one year. Standardized parallel periapical radiographs were taken every three months.

Group (T): the same procedure was applied to all root canals including the unaffected root or roots .

The periapical radiography was performed with a paralleling technique using an X-ray film holder (Rinn XCP; Dentsply, Elgin, IL, USA). The X-ray machine (CS2200; Carestream dental, Atlanta, GA, USA) was set at 60 kV and 7 mA, and exposure time for the periapical radiography ranged from 0.08 to 0.125 s (0.08 s for adult incisors and canines; 0.1 s for adult premolars; 0.125 s for adult molars). CBCT images were obtained using Care Stream CS9300 (Carestream Dental LLC, Atlanta, GA, USA) with a voxel size of 0.09mm. We conducted follow up

using standardized radiographs every three months for one year.

The peri-radicular condition was evaluated using the Periapical Index (PAI) created by Ørstavik et al. (1986)[17]. The PAI includes five grades represented on an ordinal scale as follows: (1) normal periapical structures; (2) small changes in the periapical bone or bone structure; (3) changes in the periapical bone structure with mineral loss, characteristic of apical periodontitis; (4) demineralization of the periapical bone within a well-defined radiolucent area; and (5) demineralization of the periapical bone with exacerbations and expansion in bone structure. The radiographs were evaluated independently by two examiners. Any disagreement within the evaluation of the cases was resolved by taking the average. The following cutoff points were defined to categorize the PAI values into health or diseased: 1 denoted no disease, and values from 2 to 5 indicated the presence of periapical disease. Any disagreement cases were resolved by discussion until an agreement was reached. Complete healing and incomplete healing were classified as a success, and uncertain healing and unsatisfactory healing were classified as a failure based on Molven's criteria.

3D Radiographic Healing Assessment

3D radiographic healing assessment was performed using CBCT scans by two examiners. The two examiners discussed and reached an agreement in any disagreement cases.

Statistical analysis

Data were collected, tabulated, and statistically analyzed using SPSS software 20.0 (SPSS Inc, Chicago, IL, USA). Frequencies of qualitative variables were calculated using the chi-square test.

RESULTS

Figure 1 shows the CONSORT flow diagram for this study. Fifty four study subjects were initially selected. Fourteen cases were excluded because 8 cases don't meet the criteria and 6 cases declined to participate. Forty cases were eventually included in the study and were randomly allocated to group S (20 teeth) and group T (20 teeth). The overall recall rate was 77.5% (31 of 40).

Basic patients' demographics were collected and tabulated in Table 1. Periapical index distribution and mean periapical index recorded initially and after one year are tabulated in tables 2 and 3.

Statistical analysis of patients' basic data confirmed that there was no significant difference between the two groups regarding sex ($p=0.594$), age ($p=0.721$), and type of teeth subjected to treatment ($p=0.792$).

There was no significant difference between the two groups regarding the patients' baseline mean periapical indices ($p=0.579$). Our results showed that the mean periapical index declined after one year without a significant difference between the two groups ($p=0.853$). Representative case of group S is shown in figure 2.

Figure 1. Consort flow diagram

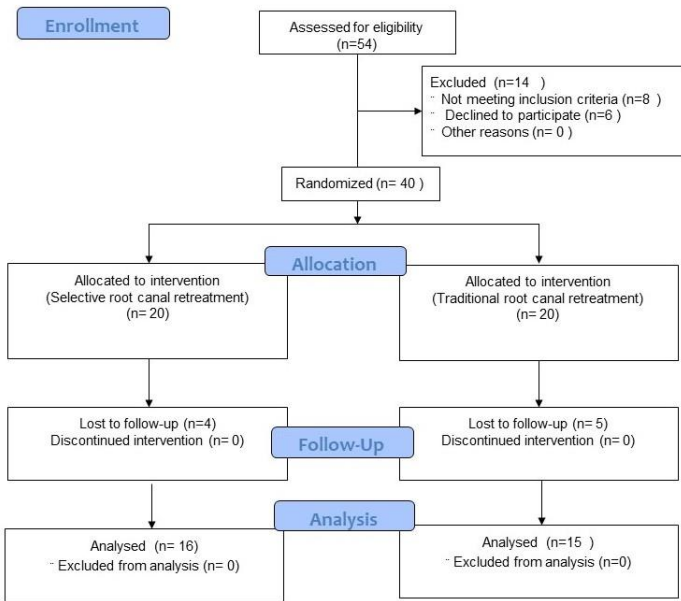


Table 1. Demographic data of participants in both groups

		Group (S)	Group (T)	P-Value
Sex	Males	9 (56%)	7 (47%)	0.594
	Females	7 (44%)	8 (53%)	
Mean Age (years)		43.9±10.5	42.5±11.2	0.721
Teeth	Maxillary Premolars	2 (12.5%)	1 (6.7%)	0.792
	Maxillary Molars	5 (31.3%)	4 (26.7%)	
	Mandibular Molars	9 (56.2%)	10 (62.6%)	

*P<0.05 is considered significant

Figure 2. CBCT views of a representative case of group (S); “Selective retreatment”, A: preoperative views showing separate periapical lesion related to the mesial root. B: One-year follow-up views showing marked healing of the lesion.

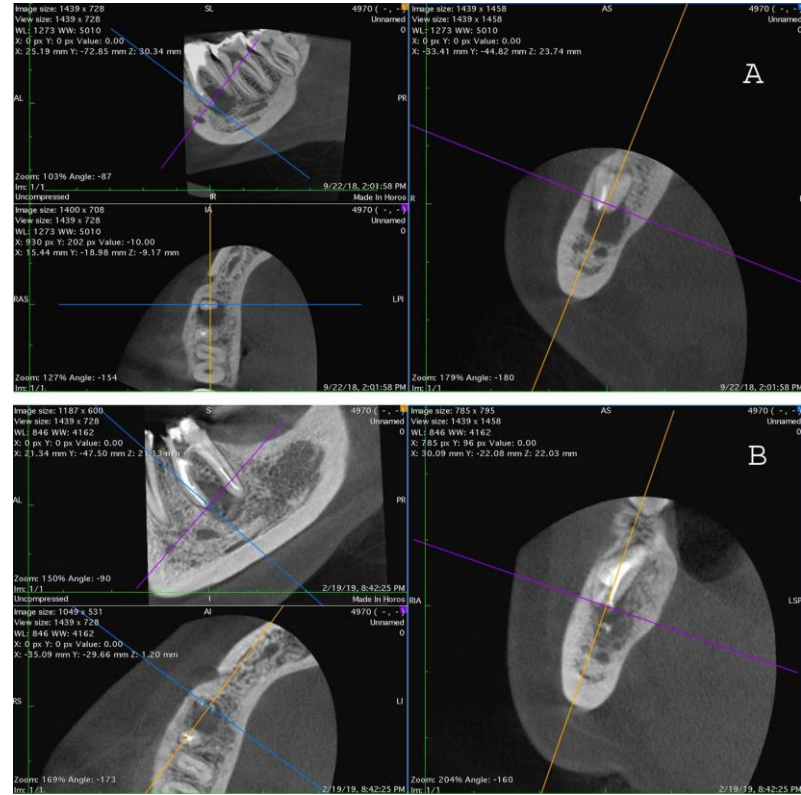


Table 2. Periapical index distribution initially and after one year of follow-up among the two tested groups.

	Group (S)		Group (T)	
	Initial score	Final score	Initial score	Final score
Stage (1)	0 (0%)	11 (68.75%)	0 (0%)	11 (73.3%)
Stage (2)	0 (0%)	4 (25%)	0 (0%)	3 (20%)
Stage (3)	3 (18.75%)	1 (6.25%)	3 (20%)	1 (6.67%)
Stage (4)	11 (68.75%)	0 (0%)	8 (53.3%)	0 (0%)
Stage (5)	2 (12.5%)	0 (0%)	4 (26.67%)	0 (0%)
Total cases	N=16		N=15	

Table 3. Mean Periapical index initially and after one year of follow-up among the two tested groups.

	Group (S)	Group (T)	P-value
Mean initial periapical index	3.94±0.574	4.07±0.704	0.579
Mean final periapical index	1.38±0.619	1.33±0.617	0.853

*P<0.05 is considered significant

DISCUSSION

Endodontically treated teeth with secondary apical periodontitis constitute a great challenge facing the endodontist. The complexity of the retreatment procedure, besides the added damage to the remaining tooth structure, remains the main issue influencing the treatment plan of such cases. The current options are limited to nonsurgical root canal retreatment, surgical root treatment, or extraction [18]. Although a successful outcome can be achieved with these alternatives, yet current advances may allow for a more conservative approach, which may yield a similarly successful outcome.

The integration between CBCT and magnification has revolutionized the field of minimally invasive endodontics. CBCT imaging has drastically improved endodontic diagnosis and treatment planning by providing a three-dimensional view of the teeth and the supporting structures [10]. The 3-planar cuts eliminate the superimposition of the overlying structures, which is always a major flaw of the regular 2-dimensional radiograph. This advantage allows for accurate and early detection of the periapical pathosis related to the apex of a single

root or roots [11]. The assessment also includes the location, size, and shape of the pulp chamber, root lengths, degree of canal curvature, and three-dimensional analysis of the causative mishaps. This capability allows for formulating a more conservative treatment plan for teeth with secondary apical periodontitis. The acquisition of a CBCT scan is thus a prerequisite during the assessment of tooth candidates for selective root retreatment procedure.

The benefit to the patients of a positive outcome of this minimally invasive technique necessitated using CBCT imaging with a slight increase in total ionizing radiation. When the selective root retreatment technique gains scientific evidence as a routine technique in daily clinical use, the outcomes can be monitored using conventional radiographs with less radiation exposure. According to the current consensus, when contamination occurs during intracanal procedures, apical periodontitis often develops quickly within one year of the initial treatment. In these instances, healing should not be expected, so one-year follow-up to evaluate the healing of intervention method was used in the

management of the retreatment cases [19, 20].

The use of a dental operating microscope has another necessity within the field of minimally invasive endodontics. Conservation of the remaining tooth structure is an essential factor influencing the prognosis and the survival rate of the tooth [21]. The ability to perform the selective retreatment procedures at high precision prevents the occurrence of additional iatrogenic damage; precise motor skills can be improved with higher magnification and in addition to a considerable reduction in treatment time for the whole procedure [22].

The literature shows scarce evidence evaluating the Selective retreatment idea or concept. Up to our knowledge, few case reports were done using this technique [15]. On the contrary, many publications support the removal of all obturation material from all canals within the tooth being retreated. The decision to selectively retreat one or more roots of a previously root-treated tooth is exclusively based on the treating clinician assessment of the case with patient acceptance.

The decision must also be based on a thorough clinical examination.

Restorations with unsatisfactory marginal integrity or recurrent caries are not candidates for that procedure as the other roots might also be infected though they appear normal. Coronal restoration works as a “barrier” to reinfection of the root canal system after endodontic treatment. That variable has been reported in the literature as an important factor related to the presence or absence of apical radiolucency. A high success rate for cases with the presence of coronal restoration was confirmed in multiple studies [23–25]. This high success rate shows that coronal restoration should be considered an important step to be taken after endodontic treatment. In our study, only cases with the intact coronal restoration were enrolled to guarantee the absence of reinfection of the other canals of the pulp system.

The decision of retreatment of the whole root canal system was made to guarantee complete eradication of the bacteria and allow for complete disinfection of the root selected for retreatment. There is a high incidence of the isthmus in molars that have been reported in many studies, the reported incidence in the mesiobuccal root of maxillary first molars is from 76%–100% and in the mesial root of mandibular first molars being approximately 83% [26–28] so in this study, the decision of retreatment of the whole root canal system was taken.

The significant limitations of the research described herein were the small sample size after dropouts and

the short length of the evaluation period, but to our knowledge, it is the first study to compare between selective root retreatment and the traditional non-conservative technique.

Within the limitation of this study, it can be concluded that selective root retreatment is a successful “minimally invasive alternative” in cases of an independently diseased root. The remaining treated roots can be retained without intervention provided that they are confirmed: “healthy”. More extended follow-up periods are recommended to validate the outcome of such cases.

REFERENCES

1. Ricucci D, Siqueira JF. Recurrent apical periodontitis and late endodontic treatment failure related to coronal leakage: A case report. *J Endod.* 2011; 37:1171–1175. PMID: 21763916
2. Siqueira JF, Rôças IN, Ricucci D, Hülsmann M. Causes and management of post-treatment apical periodontitis. *Br Dent J.* 2014; 216:305–312. PMID: 24651336
3. Costerton W, Veeh R, Shirtliff M, Pasmore M, Post C, Ehrlich G. The application of biofilm science to the study and control of chronic bacterial infections. *J. Clin. Invest.* 2003; 112:1466–1477. PMID: 14617746
4. Yan MT. The management of periapical lesions in endodontically treated teeth. *Aust Endod J* 2006; 32:2–15. PMID: 16603040
5. Roda RS, Gettleman BH. Nonsurgical Retreatment. In: *Cohen’s Pathways of the Pulp.* 2011; pp 890–952
6. Ruddle CJ. Nonsurgical retreatment. *J Endod.* 2004; 30:827–845. PMID: 15564860
7. Murdoch-Kinch CA, McLean ME. Minimally invasive dentistry. *J Am Dent Assoc.* 2003;134:87–95. PMID: 12555961
8. Nagasiri R, Chitmongkolsuk S. Long-term survival of endodontically treated molars without crown coverage: A retrospective cohort study. *J Prosthet Dent.* 2005; 93:164–170. PMID: 15674228
9. Tang W, Wu Y, Smales RJ. Identifying and Reducing Risks for Potential Fractures in Endodontically Treated Teeth. *J. Endod.* 2010; 36:609–617. PMID: 20307732
10. Ee J, Fayad MI, Johnson BR. Comparison of endodontic diagnosis and treatment planning decisions using cone-beam volumetric tomography versus periapical radiography. *J Endod* 2014; 40:910–916. PMID: 24935534
11. Patel S, Wilson R, Dawood A, Foschi F, Mannocci F. The detection of periapical pathosis using digital periapical radiography and cone beam computed tomography - Part 2: A 1-year post-treatment follow-up. *Int Endod J.* 2012; 45:711–723. PMID: 22775142
12. Lo Giudice R, Nicita F, Puleio F, Alibrandi A, Cervino G, Lizio AS, Pantaleo G. Accuracy of periapical radiography and CBCT in endodontic evaluation. *Int J Dent* 2018;2018 PMID: 30410540

13. Venskutonis T, Plotino G, Juodzbaly G, Mickevičiene L. The importance of cone-beam computed tomography in the management of endodontic problems: A review of the literature. *J. Endod.* 2014; 40:1895–1901. PMID: 25287321
14. Liang YH, Li G, Wesselink PR, Wu MK. Endodontic outcome predictors identified with periapical radiographs and cone-beam computed tomography scans. *J Endod.* 2011; 37:326–331. PMID: 21329816
15. Nudera WJ. Selective Root Retreatment: A Novel Approach. *J Endod* 2015; 41:1382–1388. PMID: 25906919
16. Faul F, Erdfelder E, Lang AG, Buchner A. G*Power 3: A flexible statistical power analysis program for the social, behavioral, and biomedical sciences. In: *Behavior Research Methods.* Psychonomic Society Inc. 2007;39:175–191. PMID: 17695343
17. Ørstavik D, Kerekes K, Eriksen HM. The periapical index: A scoring system for radiographic assessment of apical periodontitis. *Dent Traumatol* 1986; 2:20–34. PMID: 29326509
18. Aryanpour S, Van Nieuwenhuysen JP, D’Hoore W. Endodontic retreatment decisions: No consensus. *Int Endod J.* 2000; 33:208–218. PMID: 11307437
19. Ørstavik D. Time-course and risk analyses of the development and healing of chronic apical periodontitis in man. *Int Endod J.* 1996;29:150–155. PMID: 9206419
20. Anjum AS, Hegde S, Mathew S, Graduate Student P. Minimally Invasive Endodontics-A Review. *J Dent Oro-facial Res.* 2019;15:77–88. PMID: 34513652
21. Wong AW, Zhu X, Zhang S, Li SK, Zhang C, Chu CH. Treatment time for non-surgical endodontic therapy with or without a magnifying loupe. *BMC Oral Health.* 2015; 15:1–6. PMID: 25887978
22. Siqueira JF, Rôças IN, Alves FRF, Campos LC. Periradicular status related to the quality of coronal restorations and root canal fillings in a Brazilian population. *Oral Surgery, Oral Med Oral Pathol Oral Radiol Endodontology.* 2005; 100:369–374. PMID: 16122668
23. Kirkevang LL, Væth M, Hörsted-Bindslev P, Wenzel A. Longitudinal study of periapical and endodontic status in a Danish population. *Int Endod J* 2006; 39:100–107. PMID: 16454789
24. Segura-Egea JJ, Jiménez-Pinzón A, Poyato-Ferrera M, Velasco-Ortega E, Ríos-Santos JV. Periapical status and quality of root fillings and coronal restorations in an adult Spanish population. *Int Endod J.* 2004;37:525–530. PMID: 15230905
25. Borlina SC, de Souza V, Holland R, Murata SS, Gomes-Filho JE, Junior ED, de Carvalho Marion JJ, dos Anjos Neto D. Influence of apical foramen widening and sealer on the healing of chronic periapical lesions induced in dogs’ teeth. *Oral Surgery, Oral Med Oral Pathol Oral Radiol Endodontology* 2010; 109:932–940. PMID: 20451847
26. Norman Weller R, Niemczyk SP, Kim S. Incidence and position of the canal isthmus. Part 1. Mesiobuccal root of the maxillary first molar. *J Endod.* 1995; 21:380–383. PMID: 7499980
27. Cleghorn BM, Christie WH, Dong CCS. Root and Root Canal Morphology of the Human Permanent Maxillary First Molar: A Literature Review. *J Endod.* 2006; 32:813–821. PMID: 16934622
28. de Pablo ÓV, Estevez R, Sánchez MP, Heilborn C, Cohenca N. Root anatomy and canal configuration of the permanent mandibular first molar: A systematic review. *J Endod.* 2010; 36:1919–1931. PMID: 21092807