

# Evaluation of the Efficacy of 3D-guided Piezosurgery in Accelerating Mandibular Orthodontic Teeth Alignment: A Randomized Controlled Trial in Adults.

Omar Gibreal<sup>1</sup>, Yasser Al-modallal<sup>1</sup>, Maher Al-assaf<sup>2</sup>

<sup>1</sup>Department of Oral and Maxillofacial Surgery, Faculty of Dentistry, Damascus University, Damascus, Syria

<sup>2</sup>Department of Oral Histology and Pathology, Faculty of Dentistry, Damascus University, Damascus, Syria

## Abstract

**OBJECTIVE:** The aim of this study was to investigate the effects of 3D guided piezocision (a minimally invasive surgical technique) in accelerating orthodontic tooth movements (OTM) since the literature does not provide high quality evidence to confirm that Piezocision results in significant OTM acceleration. Furthermore, no randomized controlled trial (RCT) has utilized 3D piezo-surgical guides to accelerate severe orthodontic de-crowding.

**STUDY DESIGN:** A Parallel-group randomized controlled trial was conducted on patients with severe mandibular teeth irregularity. Sample size was 34 patients (19 females and 15 males), then subjects were divided into two parallel groups using Minitab® Version 17 software. First group received conventional orthodontic treatment, whereas the second group received 3D-guided piezo-assisted orthodontic one. Little irregularity index (LII) changes were studied using dental cast in four time points before inserting the first archwire (T0), after 1 month of treatment onset (T1), after 2 months (T2), and at the end of the alignment stage (T3) and the overall alignment time (OAT) required to complete anterior alignment of the mandibular arch was also measured.

**RESULTS:** Ninety-five severe dental crowding patients were evaluated for eligibility, 46 of them fulfilled the inclusion criteria. Thirty-four participants were allocated to the treatment groups randomly. There were no withdrawals during the trial phases. Accordingly, the results of 34 patients were statistically analyzed. OAT was reduced by 48% in the experimental group compared to the control group, with a statistically significant difference between the two groups. Likewise, the time difference between all arch changes was significantly lower when 3D guided piezocision was performed, except for the first arch (T0) and the last arches (T3).

**CONCLUSION:** Minimally invasive 3D guided piezocision seems to be a very effective and easy technique in accelerating orthodontic tooth movement

**KEYWORDS:** 3D surgical guide; Piezosurgery; accelerated tooth movement; minimally invasive surgery

Citation: Gibreal, O et al. (2022) Evaluation of the Efficacy of 3D-guided Piezosurgery in Accelerating Mandibular Orthodontic Teeth Alignment: A Randomized Controlled Trial in Adults  
Dentistry 3000. 1:a001 doi:10.5195/d3000.2022.281  
Received: December 18, 2021  
Accepted: April 12, 2022  
Published: August 11, 2022  
Copyright: ©2022 Gibreal, O et al. This is an open access article licensed under a Creative Commons Attribution Work 4.0 United States License.  
Email: dr.maher.assaf1990@gmail.com

## Introduction

Reduction in the duration of orthodontic treatment is considered one of the major challenges facing

orthodontists today. Moreover, prolonged orthodontic treatment times have complications such as periodontal disease, caries and root resorptions [1]. Extraction-based

orthodontic cases that could last up to 35 months are particularly vulnerable [2]. Therefore, accelerating tooth movement and shortening the treatment time have

become the common goals of both orthodontists and patients [3, 4].

Recent studies have shown that corticotomy-accelerated orthodontic treatment is associated with regional acceleration phenomenon (RAP) [5, 6, 7]. Although these corticotomies have proven their effectiveness, they are considered to be aggressive therapies [8].

Therefore, minimally invasive flapless techniques, as an alternative to traditional corticotomy, have been introduced into the orthopedic field [9-11]. Piezocision appears to be an effective, safe and minimally invasive procedure in terms of accelerating orthodontic tooth movement [12].

However, no randomized controlled trial (RCT) has employed 3D surgical guided techniques in piezocision planning. This technique could permit the engineering of an easy, accurate, predictable and safe localized alveolar decortication through a minor incision. Thus, without raising a flap, no harm would occur to any nearby anatomical structures.

So, the aim of this randomized controlled clinical trial was to investigate the effect of piezocision with a pre-customized 3D surgical guide in orthodontic treatment.

## Material and Methods

### Study design

The study was designed as a two-armed, parallel group RCT to evaluate the influence of 3D-guided piezocision-assisted orthodontic treatment (test group) compared to the traditional orthodontic treatment alone (control group). Participants were recruited from the Departments of Orthodontics at Damascus University Dental School between August 2019 and May 2021. The Local Research Ethics Committee Approval was obtained (UDDS-3656-16,032,033/SRC-5671). This trial was funded by the University of Damascus Dental School Postgraduate Research Budget (Ref no: 83054205788DEN).

### Sample size estimation

Sample size was calculated using the G\*power 3.1.7 software presuming that a reduction of 30 per cent in total treatment duration could be evidenced with a power of 80 per cent at the 5 per cent significance level. The smallest clinically significant difference in the time needed for leveling and alignment of severely crowded incisors was assumed to be 52.8 days depending on a previous report showing that crowding relief of anterior teeth took a mean of 132 days with a standard deviation 39 days [3].

Therefore, a sample of 32 patients was required for both groups. To account for possible withdrawal, the final sample size for the study was set at 17 patients per group, yielding a total of 34 patients.

### Patient selection, recruitment, and follow-up

Patients were selected from the Department of Orthodontics at University of Damascus Dental School. The treatment plan of 95 severe dental crowding patients was reviewed, but the number of patients who met the inclusion criteria and agreed to participate in this study after the acquaintance with the information sheet was 46. Thirty-four subjects were equally and randomly assigned to the two groups; figure 1 represents the CONSORT flow diagram. Information sheets were distributed to all patients and informed consents were obtained.

### Inclusion criteria

- ✓ Adult healthy patients from both sexes within an age range 17–24 years.
- ✓ Absence of previous orthodontic treatment.
- ✓ Class II division I patients requiring first upper premolars extraction.
- ✓ Severe crowding (tooth-size–arch-length discrepancy >5 mm) in the anterior mandible with Little’s irregularity index (LII).
- ✓ Completion permanent dentition (except of third molars).
- ✓ Absence of medications intake that interfere with pain perception for at least

one week before the beginning of the treatment.

**Exclusion criteria**

- ✓ Medical conditions that would affect tooth movement (corticosteroid treatments, NSAIDs consumption, bisphosphonates, hyperparathyroidism, osteoporosis, uncontrolled diabetes).
- ✓ Contraindication to oral surgery (medical–social–psychological).
- ✓ Presence of primary teeth in the mandibular arch.
- ✓ Missing permanent mandibular teeth (except for third molars).
- ✓ Previous orthodontic treatments.
- ✓ History of periodontitis with a loss of alveolar support more than 10 percent.

**Randomization and allocation concealment**

Patients were assigned to the experimental group or the control group with an allocation ratio of 1:1 using a software-generated list of random numbers. Allocation sequence was concealed using sequentially numbered, opaque, sealed envelopes which were opened only after the completion of premolars extraction. First group received 3D-guided piezocision-assisted orthodontic treatment, whereas the second group received

conventional orthodontic treatment (Figure 1). The generation of random allocation sequence, participants’ enrollment and assignment to the two groups were performed by one of the academic staff not involved in this research.

conventionally ligated. Then, a 0.014-inch NiTi archwire (American Orthodontics, Sheboygan, Wisconsin, USA) was inserted and tied to each bracket using 0.010-inch stainless steel ligature wires. For both groups, the following sequence of archwires

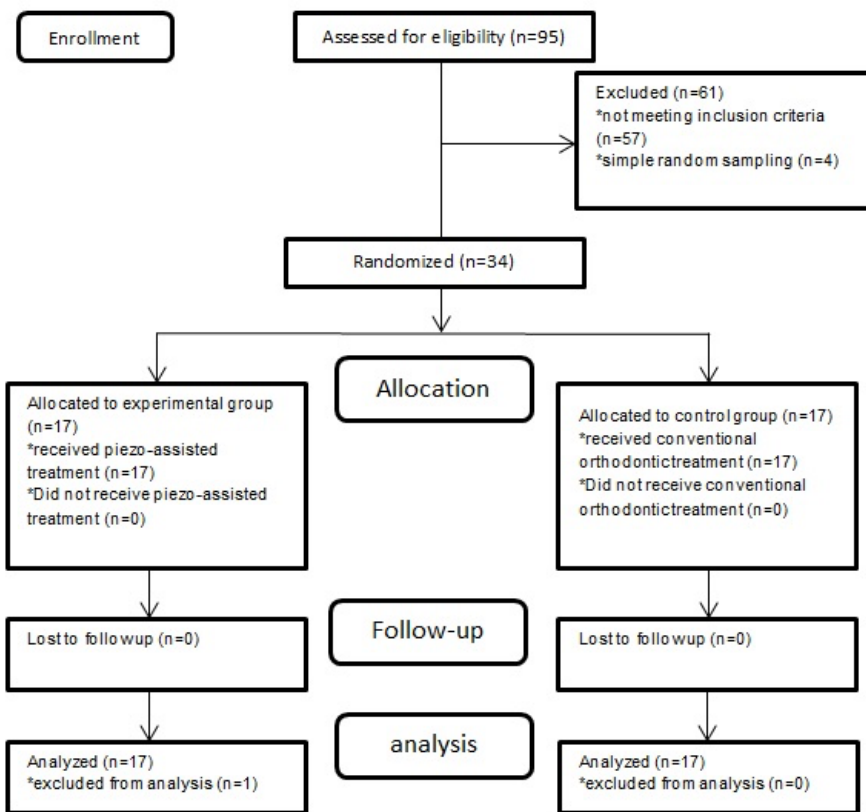


Figure 1. CONSORT flow diagram of patients’ recruitment and follow-up.

**Orthodontic procedures**

All subjects underwent conventional orthodontic treatment with fixed appliances. Fixed orthodontic appliances with an MBT prescription and 0.022-in. slot height (Master Series®, American Orthodontics™, Sheboygan, WI USA) were bonded four days following first-premolar extraction. These brackets were

was adopted: 0.014-in. NiTi followed by 0.016-in., 0.016 X 0.022-in. and 0.017 X 0.025-in. NiTi, and finally 0.019 X 0.025-in. stainless steel [11].

Patients were asked to return every 2 weeks, so that change in archwires was performed when it was felt that an improvement had occurred in teeth positions and there was a possibility of inserting the next archwire without exerting excessive

force on the engaged teeth. Treatment was considered finished when LII was less than 1 mm, indicating complete alignment of the teeth and the feasibility of inserting the final archwire passively into all brackets [13].

### 3D piezocision surgical procedure

In the test group, piezocision surgery was performed on the same premolars extraction day to minimize the number of anesthesia depending sessions in terms of patients' comfort and satisfaction. After local Infiltration was injected (lidocaine hydrochloride 2% with epinephrine 1:80,000), a pre-customized 3D surgical guide was placed to perform vertical interproximal micro-incisions (varying between 5 and 8 mm) below each interdental papilla (Figure 2).



Figure 2. 3D piezo-surgical guide.

The incisions began 4 mm below the papilla to prevent any further gingival recessions, then corticotomies (5 mm long and 3 mm deep) guided by the same 3D guide were made using a piezoelectric device (Implant Center™ 2, Satelec, France) with a BS1 cutting tip and irrigation solution pump 80 ml/m (Figure 3).

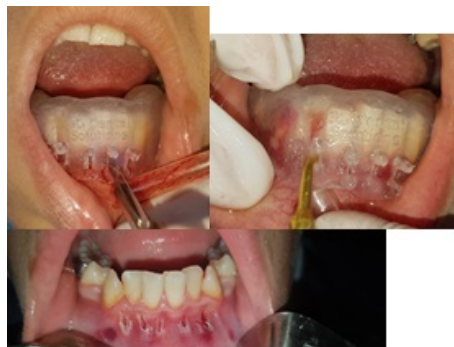

Figure 3. The guide is in place to perform the incisions and piezocisions.

All of the above-mentioned aspects were pre-planned and applied by CBCT imaging and transferred to the casts in order to produce a reliable and precise surgical 3D guide (Figure 4).

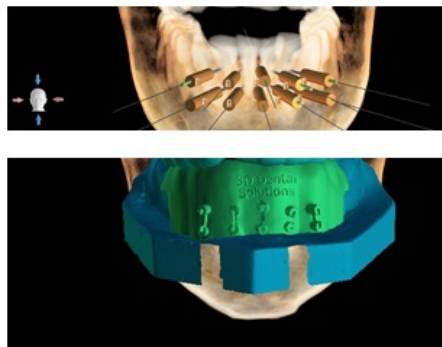


Figure 4. CBCT pre-planning.

No subsequent sutures were performed, and the surgical side was covered by a piece of Iodoform gauze. Careful tooth brushing and the use of a mouthwash (Chlorhexidine Gluconate 0.12%) were prescribed for 7 days; ice packs for the first 12 h following surgery; and patients were instructed to take one or two tables of Panadol® (acetaminophen; 500 mg) when they suffer from moderate/severe pain.

Experimental patients check-ups were scheduled a day after the procedure ensuring absence of - postoperative complications, four days post procedure to continue their orthodontic treatment and were followed up every two weeks for orthodontic treatment sequence.

### Outcome Measures

The primary outcome measure was the overall alignment time (OAT) required to complete anterior alignment of the dental arch. Follow-up of this trial was considered finished when the LII was less than 1 mm [13]. The secondary outcome measure was Little's Irregularity Index (LII) measured on study models taken at the following assessment times: before inserting the first archwire (T0), after 1 month of treatment onset (T1), after 2 months (T2), and at the end of the alignment stage which was accomplished when LII was less than 1 mm (T3). Measurements were made according to methodology mentioned by Little (13). LII was measured using a fine tip digital caliper with an accuracy of 0.1 mm (Mitutoyo, Zhejiang, China).

### Statistical analysis

Parametric tests were used since Anderson-Darling Normality tests showed normal distributions of the collected data. Two-sample t-tests were used to detect significant differences between the two groups at each assessment time. Single blinding was employed in this trial

regarding outcome measure assessment and data analysis. Minitab® program version 17.0 (Minitab Inc., Pennsylvania, USA) was used to perform descriptive and inferential statistics. Patients were given serial numbers and patients' allocation was concealed from the principal investigator through the different stages of the trial and at the statistical analysis phase to ensure blindness of the assessor and to avoid detection bias.

### Results

34 patients were enrolled in this study as presented in the basic sample characteristics Table (Table No. 1), while descriptive statistics of the evaluated variables are given in Table No. 2. No withdrawals were registered through the whole trial stages.

**Table 1:** Basic sample characteristics.

Group	Gender n (%)	P-value*	Mean Age (SD)	Min. Age	Max. Age	P-value†
Control	Male 7 (43.75%)	0.531	21.27 (1.87)	18	24	0.092
	Female 9 (56.25%)					
Experimental	Male 8 (44.4%)					
	Female 10 (55.6%)					
All sample	34 (100%)		21.03 (1.96)	17	24	

\*: employing chi-square test, †: employing two-sample t test, Min: minimum, Max: maximum

A statistical significance was found between the two groups regarding the OAT. The experimental group required less mean treatment time (i.e. 61.9 ± 12.5 days) in the leveling and alignment stage compared to the control group (i.e. 129.1 ± 35.5 days; P <0.0001) with a 48% decrease in the OAT.

The results regarding changes of the LII according to assessed time points are given in (Table No. 3). No statistically significant difference between the two groups was found at T0 and T3 (P = 0.511, P=0.832, respectively), whereas statistically significant differences were observed at T1 and T2 (P <0.001, P=0.003, respectively).

### Discussion

This is the first published RCT having the objective of employing 3D guiding

techniques in accelerating severe orthodontic teeth de-crowding utilizing piezocision. It was found that 3D guided piezocision accelerated leveling and alignment and reduced the overall time by about 48%. This could be explained by the regional acceleratory phenomenon (RAP) following the intentional bone injury [7, 14]. This result was in accordance with some other recent clinical trials studying the effectiveness of the flapless piezocision technique in accelerating teeth leveling and alignment. In comparable recent studies [3, 5, 15, 16], similar acceleration rates in the piezocision groups were found. None of them used 3D guiding techniques to achieve safe and accurate piezoelectric cortectomies. However, the trial that had performed guided piezocortcision utilized mild non extraction crowding cases.



**Table 2:** Descriptive statistics of the Little’s index of irregularity (mm) and the overall alignment time (days) in the two groups (n = 17 for each group).

Variable	Group	Mean	SD	SE	Min	Q1	Median	Q3	Max
LIIT0	Control	11.66	1.17	0.24	10.00	10.88	11.00	12.00	13.00
	Exp	11.59	0.69	0.32	10.00	10.84	11.50	12.25	14.00
LIIT1	Control	8.90	1.14	0.25	6.50	7.25	8.50	9.00	10.00
	Exp	4.35	1.67	0.42	4.00	4.75	5.00	5.25	6.00
LIIT2	Control	5.75	1.12	0.28	4.50	5.00	5.50	6.25	7.80
	Exp	2.91	0.34	0.21	2.00	2.57	2.75	2.89	3.50
LIIT3	Control	0.32	0.12	0.02	0.10	0.25	0.30	0.40	0.50
	Exp	0.24	0.10	0.02	0.10	0.20	0.20	0.30	0.40
OTT	Control	129.11	35.53	7.55	98.00	101.50	121.00	130.50	179.00
	Exp	61.90	12.52	4.33	49.00	51.00	58.00	62.50	81.00

LIIT0: Little’s irregularity index before inserting the first archwire; LIIT1: after 1 month of orthodontic treatment onset; LIIT2: after 2 months; LIIT3: at the end of the alignment stage; Exp.: experimental group; SD: Standard Deviation; SE: Standard Error; Min: minimum; Q1: first quartile; Q3: third quartile, Max: maximum.

**Table 3:** The results of significance tests of the observed LII changes (in mm); (n=17 in each group)†.

Little's Index of Irregularity	Group	Mean	SD	Mean Difference (%)	95% CI of the difference		P-value	Significance of differences
					Lower Bound	Upper Bound		
Before	Control	11.66	1.17	-0.226	-1.004	0.510	0.671	NS
	Experimental	11.59	0.69					
At one month	Control	8.90	1.14	3.2899	3.192	5.488	<0.0001	**
	Experimental	5.25	1.67					
At two months	Control	5.66	1.12	1.8099	1.074	4.544	0.002	*
	Experimental	2.95	0.34					
At three months	Control	0.32	0.12	0.0824	0.0050	0.1597	.0545	NS
	Experimental	0.24	0.10					

†: Two sample t test, \*: significant at P<0.05, \*\*: significant at P<0.001, NS: Not significant.

In contrast, Uribe et al reported no significant difference in the alignment time between the conventional and the piezosurgery groups [17]. The difference between our findings and theirs is probably related to the fact that they applied just three cortical incisions in the labial cortical plate (4-mm length and 1-mm depth of cortical bone) between the

mandibular central incisors, and lateral incisors and canines, while in the current study, five cortical incisions in the labial cortical plate (5- to 8-mm length and 3-mm depth of cortical bone) between the six anterior teeth. Additionally, patients in the current study underwent extraction of first premolars which

may have enhanced the effect of the RAP [8, 18].

Other RCTs carried out in the past few years regarding the efficacy of piezosurgery in accelerating other orthodontic treatments such as canine retraction [19-21] and en masse retraction [22]. Alfawal et al. in a RCT [19] evaluated the effectiveness of piezosurgery in the

acceleration of upper canine retraction after first premolar extraction. This showed that the rate of upper canine retraction was significantly higher in the experimental side compared to the control side, by two-fold the first month and 1.5-fold in the second month. These findings are comparable with the studies of Abbas et al [21] and Aksakalli et al [20] that reported an acceleration of the rate of canine retraction by 1.5–2 times during the first 3 months of tooth movement when piezocision was used. To the contrary, Tunçer et al [22] concluded that piezo surgery was ineffective in accelerating en masse retraction for upper anterior teeth following premolar extraction in Class II division 1 patients. The lack of significant results may be explained by underpowered sample size calculation of that study, intending to detect at least 50 per cent difference in the rate of tooth movement instead of 30 per cent as in our study. Nevertheless, the direct comparison between our findings and those studies is not straightforward since these RCTs have been based on canine or en-masse retraction and not crowding relief corrections. No significant difference at T0 in LII was found, which assured that the groups were almost similar in the initial crowding. Furthermore, after a month LII had a mean of 4.25 mm ( $\pm$  1.67) in the experimental group and a mean of 8.9 mm ( $\pm$  1.14) for the control group. These results indicated

a 51% higher leveling rate for the experimental group than the control one. This percentage slightly decreased to 49% after 2 months; but further decreased to 25% at the end of the alignment stage (T3). This decrease could be explained by the gradual decrease of the RAP over time which was documented by Wilcko et al., however they report an onset after 1–2 months following bone injury and found that the effects lasted from 2 to 4 months [23].

### Conclusion

Minimally invasive 3D guided Piezocision seems to be a very effective and easy technique in accelerating orthodontic tooth movement.

### References

1. Adverse effects of orthodontic treatment: A clinical perspective. Talic NF. Saudi Dent J. 2011 Apr;23(2):55-59. doi: 10.1016/j.sdentj.2011.01.003. PMID: 24151415.
2. Corticotomy facilitated orthodontics: Review of a technique. Alghamdi AS. Saudi Dent J. 2010 Jan;22(1):1-5. doi: 10.1016/j.sdentj.2009.12.008. PMID: 23960473.
3. Efficacy of piezocision-based flapless corticotomy in the orthodontic correction of severely crowded lower anterior teeth: a randomized controlled trial. Gibreal O, Hajeer MY, Brad B. Eur J Orthod. 2019 Mar 29;41(2):188-195. doi: 10.1093/ejo/cjy042. PMID: 29931294.

4. Acceleration of tooth movement during orthodontic treatment--a frontier in orthodontics. Nimeri G, Kau CH, Abou-Kheir NS, Corona R. Prog Orthod. 2013 Oct 29;14:42. doi: 10.1186/2196-1042-14-42. PMID: 24326040.
5. Localized Piezoelectric Alveolar Decortication for Orthodontic Treatment in Adults: A Randomized Controlled Trial. Charavet C, Lecloux G, Bruwier A, Rompen E, Maes N, Limme M, Lambert F. J Dent Res. 2016 Aug;95(9):1003-1009. doi: 10.1177/0022034516645066. PMID: 27129491.
6. Piezocision™-assisted orthodontics: Past, present, and future. Dibart S, Keser E, Nelson D. Semin Orthod. 2015;21(3):170-175. doi: 10.1053/j.sodo.2015.06.003.
7. The regional acceleratory phenomenon: a review. Frost HM. Henry Ford Hosp Med J. 1983;31(1):3-9. PMID: 6345475.
8. Mechanism of action and morphologic changes in the alveolar bone in response to selective alveolar decortication-facilitated tooth movement. Baloul SS, Gerstenfeld LC, Morgan EF, Carvalho RS, Van Dyke TE, Kantarci A. Am J Orthod Dentofacial Orthop. 2011 Apr;139(4 Suppl):S83-101. doi: 10.1016/j.ajodo.2010.09.026. PMID: 21435543.
9. Effects of Corticision on paradental remodeling in orthodontic tooth movement. Kim SJ, Park YG, Kang SG. Angle Orthod. 2009 Mar;79(2):284-291. doi: 10.2319/020308-60.1. PMID: 19216591.
10. Effect of corticision and different force magnitudes on orthodontic tooth movement in a rat model. Murphy CA, Chandhoke T, Kalajzic Z, Flynn R, Utreja A, Wadhwa S, Nanda R, Uribe F.

- Am J Orthod Dentofacial Orthop. 2014 Jul;146(1):55-66. doi: 10.1016/j.ajodo.2014.03.024. PMID: 24974999.
11. Evaluation of the levels of pain and discomfort of piezocision-assisted flapless corticotomy when treating severely crowded lower anterior teeth: a single-center, randomized controlled clinical trial. Gibreal O, Hajeer MY, Brad B. BMC Oral Health. 2019 Apr 16;19(1):57. doi: 10.1186/s12903-019-0758-9. PMID: 30991984.
  12. Piezocision™: Accelerating Orthodontic Tooth Movement While Correcting Hard and Soft Tissue Deficiencies. Dibart S. Front Oral Biol. 2016;18:102-108. doi: 10.1159/000351903. PMID: 26599123.
  13. The irregularity index: a quantitative score of mandibular anterior alignment. Little RM. Am J Orthod. 1975 Nov;68(5):554-563. doi: 10.1016/0002-9416(75)90086-x. PMID: 1059332.
  14. Orthodontic method and device. Wilcko MT, Wilcko WM. United States patent US 6,109,916. 2000 Aug.
  15. Piezocision-assisted orthodontic treatment using CAD/CAM customized orthodontic appliances: a randomized controlled trial in adults. Charavet C, Lecloux G, Jackers N, Albert A, Lambert F. Eur J Orthod. 2019 Sep;41(5):495-501. doi: 10.1093/ejo/cjy082. PMID: 30649257.
  16. Piezocortico-cision-assisted orthodontics: Efficiency, safety, and long-term evaluation of the inflammatory process. Strippoli J, Durand R, Schmittbuhl M, Rompré P, Voyer R, Chandad F, Nishio C. Am J Orthod Dentofacial Orthop. 2019 May;155(5):662-669. doi: 10.1016/j.ajodo.2018.06.013. PMID: 31053282.
  17. Efficiency of piezotome-cortico-cision assisted orthodontics in alleviating mandibular anterior crowding-a randomized clinical trial. Uribe F, Davoody L, Mehr R, Jayaratne YSN, Almas K, Sobue T, Allareddy V, Nanda R. Eur J Orthod. 2017 Nov 30;39(6):595-600. doi: 10.1093/ejo/cjw091. PMID: 28371882.
  18. Cytokine expression and accelerated tooth movement. Teixeira CC, Khoo E, Tran J, Chartres I, Liu Y, Thant LM, Khabensky I, Gart LP, Cisneros G, Alikhani M. J Dent Res. 2010 Oct;89(10):1135-1141. doi: 10.1177/0022034510373764. PMID: 20639508.
  19. Evaluation of piezocision and laser-assisted flapless corticotomy in the acceleration of canine retraction: a randomized controlled trial. Alfawal AMH, Hajeer MY, Ajaj MA, Hamadah O, Brad B. Head Face Med. 2018 Feb;14(1):4. doi: 10.1186/s13005-018-0161-9. PMID: 29454369.
  20. Accelerated tooth movement with piezocision and its periodontal-transversal effects in patients with Class II malocclusion. Aksakalli S, Calik B, Kara B, Ezirganli S. Angle Orthod. 2016 Jan;86(1):59-65. doi: 10.2319/012215-49.1. PMID: 25989211.
  21. Evaluation of cortico-cision-facilitated orthodontics and piezocision in rapid canine retraction. Abbas NH, Sabet NE, Hassan IT. Am J Orthod Dentofacial Orthop. 2016 Apr;149(4):473-480. doi: 10.1016/j.ajodo.2015.09.029. PMID: 27021451.
  22. Efficiency of piezosurgery technique in miniscrew supported en-masse retraction: a single-centre, randomized controlled trial. Tunçer NI, Arman-Özçirpici A, Oduncuoglu BF, Göçmen JS, Kantarci A. Eur J Orthod. 2017 Nov;39(6):586-594. doi: 10.1093/ejo/cjx015. PMID: 28402521.
  23. Accelerated osteogenic orthodontics technique: a 1-stage surgically facilitated rapid orthodontic technique with alveolar augmentation. Wilcko MT, Wilcko WM, Pulver JJ, Bissada NF, Bouquet JE. J Oral Maxillofac Surg. 2009 Oct;67(10):2149-2159. doi: 10.1016/j.joms.2009.04.095. PMID: 19761908.