

# Association of sella turcica bridging and morphologic characteristics with palatally impacted canine in lateral cephalograms.

Nikoo Ghasemi<sup>1</sup>, Soraya Akhoondi<sup>2</sup>, Zohre Reyhani<sup>3</sup>, Nima Motamed<sup>4</sup>, Azin Nourian<sup>5</sup>

<sup>1</sup>Dental Student, School of Dentistry, Zanjan University of Medical Sciences, Zanjan, Iran

<sup>2</sup>Dentist, private practice, Zanjan, Iran

<sup>3</sup>Assistant Professor, Department of Dental Radiology, School of Dentistry, Zanjan University of Medical Sciences, Zanjan, Iran

<sup>4</sup>Associate Professor, Department of Social Medicine, Zanjan University of Medical Sciences, Zanjan, Iran

<sup>5</sup>Assistant Professor, Orthodontic Department, Zanjan University of Medical Sciences, Zanjan, Iran

## Abstract

**INTRODUCTION:** Researchers have been interested in the relationship between sella turcica bridging and various dental anomalies. This study investigates the association of sella turcica bridging and morphologic characteristics with the palatally impacted canine tooth.

**MATERIALS AND METHODS:** Orthodontic records with high-quality lateral cephalometric and panoramic images were chosen. The study comprised 30 patients with palatally impacted canines (17 females and 13 males) and 30 controls with erupted canines (15 males and 15 females). The measurements were performed using the SCANORA 5.2.6 software. Further, the relevant data was collected and analyzed using SPSS software version 22. Descriptive statistical analysis was used to investigate data after their validation, with t-tests and chi-square tests to compare the two groups. The regression test was used to lessen the effects of confounding variables.

**RESULTS:** In the study group, 5 patients had type III sella turcica bridging, whereas 2 patients in the control group had type III sella turcica bridging. Results showed a statistically significant difference between the two groups (P-value=0.017). In the study group, the interclinoid distance and canine tooth angle were significantly lower than the control group (P-value=0.001, P-value=0.001). However, there were no significant differences in the depth and anterior-posterior diameter of sella turcica between the two groups (P-value=0.543, P-value=0.766). In terms of age (P-value = 0.400) and gender (P-value = 0.605), there was no significant difference between the two groups.

**CONCLUSION:** The palatally canine impaction may be associated with the bridging of the sella turcica. Therefore, sella turcica bridging can be used as a diagnostic parameter for palatally canine impaction.

**KEYWORDS:** Tooth abnormalities; Orthodontics; Sella turcica

Citation: Ghasemi, N et al. (2022) Association of sella turcica bridging and morphologic characteristics with palatally impacted canine in lateral cephalograms. Dentistry 3000. 1:a001 doi:10.5195/d3000.2022.254  
Received: October 16, 2021  
Accepted: April 23, 2022  
Published: June 23, 2022  
Copyright: ©2022 Ghasemi, N et al. This is an open access article licensed under a Creative Commons Attribution Work 4.0 United States License.  
Email: azin.nourian@gmail.com

## Introduction

Sella turcica, an important anatomical landmark in lateral cephalometric

imaging, is an area in the form of a saddle that is based in the middle part of the cranial fossa[1]. It is also

an important finding for orthodontists since many pathological processes are shown by

changes in the form and dimensions of the sella turcica. Sella turcica is classified into three groups: circular, oval and flat shapes. The most common among them is the circular, followed by oval and flat respectively [2]. Sella turcica bridging could be a common variation of sella turcica, possibly related to numerous systemic developmental syndromes [3]. According to the theories expressing that mutations of the HOX hedgehog gene negatively affect the midface, teeth and part of the sella turcica development, any modifications in the developmental level could result in sella turcica bridging that might further cause dental anomalies [4]. Dental anomalies can be caused by various factors, including genetic, epigenetic, and environmental influences [5]. Although many studies have been conducted on the common occurrence of various dental irregularities, few have looked into the connection between bridging of the sella turcica and dental anomalies [6].

Canine impaction is one of the types of dental anomalies. For many years, orthodontists have struggled with canine impaction. Examinations can be an effective way to reduce the cost and treatment time of the patients [7]. Excluding the third molars, the maxillary canine is the most commonly impacted [8]. Furthermore, impaction is more common in women [9]. Canine impaction in about 15% of cases is

located buccally while in about 85% it is located palatally [10]. Buccal canine impaction is originally caused by dental crowding [11]. While palatally canine impactions frequently, but not always, are found in dentitions with various anomalies [12].

Some studies claim that sella turcica bridging is more common in patients with impacted canines [7, 13], while others claim there is no significant link between impacted canines and sella turcica bridging [14, 15].

As there are few studies about the association of sella turcica bridging and morphologic characteristics with canine impaction as well as contradictory comments, further studies are needed [16]. Therefore, this study aims to determine sella turcica morphologic characteristics and the possible relationship between the sella turcica bridging and the palatally canine impaction in lateral cephalometric radiographs.

## Material and Methods

This retrospective case-control study with convenience sampling evaluated 30 patients (17 females and 13 males) with at least one palatally impacted maxillary canine compared with 30 patients (15 females and 15 males) with normally erupted canines matched in terms of age and gender. This study was conducted to determine the association between palatally canine impaction and sella turcica bridging using orthodontic patients' pretreatment radiographic

records referred to private oral and maxillofacial radiology centers in Zanjan city (Iran), from 2017 to 2020, with an equal racial background as Iranian root. Approval from the Ethics Committee of Zanjan Dental school was obtained (number IR.ZUMS.REC.1398.417). All the patients who participated in the study signed written informed consent.

The inclusion criteria were 13-30 years old orthodontic patients with good quality standardized panoramic and lateral cephalograms were included in the study. Patients who had dental malformations and syndromes, significant illnesses or medical conditions as well as cases with blurred radiographic appearance and a history of orthognathic surgery, orthodontic treatment, cleft lip and palate, maxillofacial pathology, trauma were excluded from this study. The study group consisted of 30 patients (17 females and 13 males) with at least one palatally impacted maxillary canine and the control group of 30 patients (15 females and 15 males) with normally erupted canines no dental abnormalities. The two groups were matched in terms of age and sex. (Table 1)

The pretreatment orthodontic panoramic and lateral cephalometric radiographs were used to diagnose tooth impaction or eruption [18]. To determine the palatally impaction of canine teeth, panoramic and lateral cephalometry radiographs and all other sources of information available, such as cone beam

computed tomography, occlusal view radiographs were used, in some cases referring to orthodontic diagnostic records. The radiographic parameters studied were the interclinoid distance (the distance between the tip of the tuberculum sellae and the dorsum sellae), sella turcica depth (the length of a line dropped perpendicularly from the line above to the deepest point on the sella floor), anteroposterior diameter of the sella turcica (the longest distance between the tip of the tuberculum sellae and the posterior contour of the sella), sella turcica bridging and canine angle. The SCANORA 5.2.6 software was used to conduct measurements. The line drawn from the highest point of the condyles was used to compute the canine angle. (Figure 1)

A standard scoring scale devised by Leonardi et al was used to assess the degree of sella turcica bridging[19]. Type I: normal sella turcica, interclinoid distance equal to or greater than three-quarters of the largest anteroposterior diameter. Type II: incomplete calcification, interclinoid distance equal to or lower than three-quarters of the largest anteroposterior diameter. Type III: complete calcification, only the sella turcica diaphragm is visible on radiography. (Figure 2)

is presented in the table 2. SPSS software version 22 was used to analyze data. Descriptive statistical analysis was utilized and to compare the two groups, t-test and chi-square tests were performed.

**Results**

A total of 60 radiographic records of patients were investigated. To assess data distribution, Kolmogorov-Smirnov test was employed. The results of the normality test showed normal distribution (P-value>0.05).

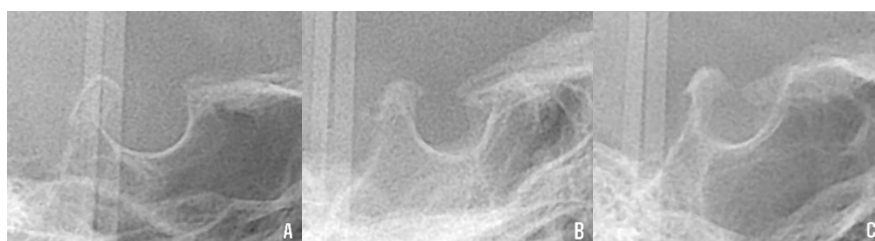


Figure 2. Examples of different types of Sella turcica bridging, A: Type I, B: Type II, C: Type III

Lateral cephalometric radiographs were used to assess the sella turcica, performed by an expert oral and maxillofacial radiologist. To confirm the accuracy of the measures, 10 samples were re-examined at two-week intervals to ensure the reliability and reproducibility of the assessments. No significant difference was found (P-value>0.05). The intraclass correlation coefficient (ICC)

We used t-test, two groups proportion and chi-square test to compare the data between two groups. The Mean±SD of the age of control group and study group was 17.87±3.04 and 18.57±3.35, respectively. The study group consisted of 30 patients (17 females and 13 males) and the control group of 30 patients (15 females and 15 males). In terms of age (P value = 0.400) and gender (P value = 0.605), there was no significant difference between the

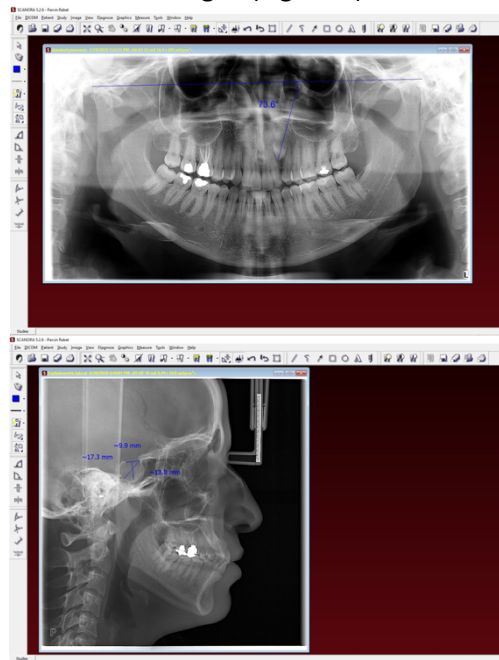


Figure 1. Two views of SCANORA version 5.2.6 software showing how to measure variables of Interclinoid distance, sella turcica depth, anteroposterior diameter of sella turcica bridging and canine angle

Table 2: Method Error According to Intraclass correlation coefficient

Variables	Intraclass correlation coefficient (ICC)
Interclinoid distance	0.966
Sella turcica depth	0.921
Ant-Post diameter of sella turcica	0.947
Canine angle	0.928

two groups of patients. In the study group 33.3%(n=10), 50%(n=15) and 16.7%(n=5) of patients had type I, type II and type III of sella turcica bridging, respectively whereas in the control group, 70%(n=21), 23.3%(n=7), 6.7%(n=2) of patients had type I, type II and type III of sella turcica bridging, respectively. This resulted in a statistically significant difference(P-value=0.017). (Table 1)

**Table 1:** Demographic and types of sella turcica bridging in the two groups

Variables		Study group	Control group	P-value
Age		18.57±3.35	17.87±3.04	0.400
Male/female		13/17	15/15	0.605
Sella turcica bridging	Type I	10(33.3%)	21(70%)	0.017
	Type II	15(50%)	7(23.3%)	
	Type III	5(16.7%)	2(6.7%)	

In the study group 20 patients had unilateral and 10 patients had bilateral canine impaction. While the total occurrence of canine impaction in maxillary left and right side was 54.5% (n=12) and 45.5% (n=10) in female respectively, this was 55.6% (n=10) and 44.4% (n=8) in male (Z=0.06, P-value=0.949).

The measures of study group's interclinoid distance was significantly shorter than the control group (P-value = 0.001) as well as the canine angle which was significantly lower in the study group. (P- value = 0.001). However, the depth of the sella turcica and anteroposterior diameter of sella was not significantly different between the two groups with P-value 0.543 and 0.766, respectively. (Table 3)

## Discussion

The sella turcica is a structure that may be easily traced in cephalometric analysis and may be seen clearly on lateral cephalometric radiographs. The shape of the sella turcica is very important in orthodontics because it serves as a reference point in orthodontic analysis[20].

We opted to investigate the

association between sella turcica bridging and canine impaction and compare it to normal canine eruption due to the importance of its characteristics, such as morphology and size, as factors that can alter the pituitary gland's pathologic status. The results of this study revealed that patients with canine impaction had considerably higher sella turcica bridging. Furthermore, the interclinoidal distance and canine

angle of the study group were significantly lower than those of the control group. The depth of the sella turcica and the anteroposterior width of the sella turcica did not differ significantly. The findings of this investigation were in line with the majority of previous studies[7, 13, 19].

In line with the present study, Dadgar et al.(2020) conducted a study in 46 patients with canine impaction and 46 patients with normal canine eruption. The results showed that palatal canine impaction is positively associated with both atlas arcuate foramen and sella turcica bridging. However, the arcuate foramen was not investigated, but morphological characteristics of sella turcica were defined in the present study[13].

In the Baidas et al.(2018) study there was no difference in the morphology of the sella turcica between patients with and without canine impaction. The incidence of sella turcica bridging was observed to be considerably greater in patients with canine impaction (P-value 0.0001)[19]. The

**Table 3:** Measures of Sella turcica morphologic characteristics in two groups

Variables	Mean±SD		P-Value
	Study group	Control group	
Interclinoid distance	4.86±0.47	5.96±1.20	0.001
Sella turcica depth	7.30±1.57	6.89±0.94	0.543
Ant-Post diameter of sella turcica	9.04±1.98	8.77±1.67	0.766
Canine angle	57.40±12.63	89.66±5.28	0.001

results are consistent with the present study.

Haji ghadimi et al. (2017) concluded that the impacted canine is related to the sella turcica bridging occurrence and severity in a case control study on lateral cephalometric records of 35 patients with canine impaction and 75 patients with normal canine eruption. The results are similar to the present study, although in the present study, morphological characteristics of sella turcica were also investigated [3].

In a study, Batool ali et al. (2014) compared 31 patients with canine impaction to 70 patients with normal canine eruption. The study's findings were consistent with the current study, revealing that the incidence of sella turcica bridging was considerably higher in the study group than in the control group (P value = 0.001). In addition, the sagittal interclinoidal distance was significantly reduced. (P value=0.028) [7].

Leonardi et al. (2006) also studied 34 individuals with maxillary impacted canine anomalies and determined that there is a relationship between impacted canine and sella turcica bridging, although there are no significant differences based on age or gender [6]. In this investigation as well, we observed no significant association between age and sex.

Unlike the current study, Ortiz et al. (2018) discovered no significant

relationship between maxillary palatally impacted canine and sella turcica bridging in 38 patients with maxillary palatally impacted canine and 38 patients without any dental anomaly. Maybe their different results from our study are due to their diagnostic radiographic records (cone beam computed tomography images) [14]. In their investigation, El Wak et al. found no significant link between sella turcica bridging and canine impaction, which contradicted our findings[15]. However, despite other research and our investigation revealing a significant relationship, these two studies with small sample sizes found no significant association between canine impaction and sella turcica bridging.

There are several theories on the pathophysiologic cause of the association of canine impaction and sella turcica bridging. The Sella turcica is the primary site for neural crest cell migration. Mutations in the Homebox, Hox, or Sonic hedgehog genes have a deleterious impact on the growth of the central section of the face, teeth, and sections of the sella turcica. Because canine teeth and sella turcica originate from the same place, modifications throughout growth and development might result in sella turcica bridging and canine impaction[20, 21]. As a result, this anomaly could be used as a marker, allowing orthodontists and radiologists to detect and predict pituitary gland disorders in this critical location.

The scope of our research was constrained by a few variables. The study used lateral cephalograms, which are a two-dimensional representation of a three-dimensional subject with its own set of landmark recognition and tracing errors. Due to the COVID-19 pandemic, few patients were involved in our study, but although it resulted in a smaller sample size, this sample size was adequate to obtain proper test power in terms of most variables which were investigated in this study. Further studies in larger communities with different ethnic backgrounds and more thorough examination of the patient's profile (e.g., height, BMI, family history, underlying condition, etc.) and using cone beam computed tomographic records instead of lateral cephalometric records are recommended.

## Conclusion

The results showed that the incidence of sella turcica bridging was greater in individuals with maxillary canine impaction than in the control group. In addition, the interclinoidal distance and canine angle were lower in the study group than in the control group, despite the fact that the depth of the sella turcica and the anterior-posterior diameter of the sella turcica were not substantially different.

As a conclusion, palatally canine impaction may be related to the bridging of the sella turcica. Therefore, sella turcica bridging can



be used as a diagnostic parameter for palatally canine impaction.

## Acknowledgement

The present study was extracted from a thesis approved and funded by the Faculty of Dentistry of Zanjan University of Medical Sciences (Ethics Code: IR.ZUMS.REC.1398.417). The authors would like to express their gratitude to all staffs who cooperated in this research.

## References

1. Bridging and dimensions of sella turcica in subjects treated by surgical-orthodontic means or orthodontics only. Jones R, Faqir A, Millett D, Moos K, McHugh S. *The Angle Orthodontist*. 2005;75(5):714-8. PMID: 16279819.
2. Sella turcica-Its importance in orthodontics and craniofacial morphology. Sathyanarayana HP, Kailasam V, Chitharanjan AB. *Dental research journal*. 2013 Sep;10(5):571. PMID: 24348611
3. Associations among sella turcica bridging, atlas arcuate foramen (ponticulus posticus) development, atlas posterior arch deficiency, and the occurrence of palatally displaced canine impaction. Ghadimi MH, Amini F, Hamed S, Rakhshan V. *American Journal of Orthodontics and Dentofacial Orthopedics*. 2017;151(3):513-20. PMID: 28257736
4. Neural crest contribution to mammalian tooth formation. Miletich I, Sharpe PT. *Birth Defects Research Part C: Embryo Today: Reviews*. 2004;72(2):200-12. PMID: 15269893
5. Multilevel complex interactions between genetic, epigenetic and environmental factors in the aetiology of anomalies of dental development. Brook AH. *Archives of oral biology*. 2009 Dec 1;54:S3-17. PMID: 19913215
6. A sella turcica bridge in subjects with dental anomalies. Leonardi R, Barbato E, Vichi M, Caltabiano M. *The European Journal of Orthodontics*. 2006;28(6):580-5. PMID: 16954179
7. Association between sella turcica bridging and palatal canine impaction. Ali B, Shaikh A, Fida M. *American Journal of Orthodontics and Dentofacial Orthopedics*. 2014;146(4):437-41. PMID: 25263146
8. Frequency of impacted teeth and categorization of impacted canines: A retrospective radiographic study using orthopantomograms. Al-Zoubi H, Alharbi AA, Ferguson DJ, Zafar MS. *European journal of dentistry*. 2017 Jan;11(01):117-21. PMID: 28435377
9. A survey of 3,874 routine full-mouth radiographs: II. A study of impacted teeth. Dachi SF, Howell FV. *Oral Surgery, Oral Medicine, Oral Pathology*. 1961;14(10):1165-9. PMID: 13883048
10. The ectopic maxillary canine: a review. *British Journal of Orthodontics*. Mcsherry PF. 1998;25(3):209-16. PMID: 9800020
11. Is there a relationship between third-molar impaction types and the dimensional/angular measurement values of posterior mandible according to Pell & Gregory/Winter Classification? Gümürükçü Z, Balaban E, Karabağ M. *Oral radiology*. 2020:1-7. PMID: 31925627
12. Maxillary tooth size variation in dentitions with palatal canine displacement. Becker A, Sharabi S, Chaushu S. *The European Journal of Orthodontics*. 2002;24(3):313-8. PMID: 12143095
13. Associations among palatal impaction of canine, sella turcica bridging, and ponticulus posticus (atlas arcuate foramen). Dadgar S, Alimohamadi M, Rajabi N, Rakhshan V, Sobouti F. *Surgical and Radiologic Anatomy*. 2021;43(1):93-9. PMID: 32816070
14. A CBCT Investigation of the Association between sella-turcica bridging and maxillary palatal canine impaction. Ortiz PM, Tabbaa S, Flores-Mir C, Al-Jewair T. *BioMed research international*. 2018;2018. PMID: 29682544
15. Association between sella turcica bridging and palatal canine impaction: evaluation using lateral cephalograms and CBCT. El Wak T, Akl R, Mati M, Khoury E, Ghoubril J. *International orthodontics*. 2018;16(2):338-48. PMID: 29628424
16. Sella Turcica Morphology on Cephalometric Radiographs and Dental Abnormalities—Is There Any Association?—Systematic Review. Jankowski T, Jedliński M, Grocholewicz K, Janiszewska-Olszowska J. *International Journal of Environmental Research and Public Health*. 2021;18(9):4456. PMID: 33922272
17. An association between sella turcica bridging and dental transposition. Leonardi R, Farella M, Cobourne MT. *The European Journal of Orthodontics*. 2011;33(4):461-5. PMID: 21212168
18. Skeletal anomalies and normal variants in patients with palatally displaced canines. Leonardi R, Barbato E, Vichi M,

Caltabiano M. The Angle  
Orthodontist. 2009;79(4):727-  
32. PMID: 19537879

19. Association of sella turcica bridging with palatal canine impaction in skeletal Class I and Class II. Baidas LF, Al-Kawari HM, Al-Obaidan Z, Al-Marhoon A, Al-Shahrani S. Clinical, cosmetic and investigational dentistry. 2018;10:179. PMID: 30154673
20. Relationship between the maxillary transverse dimension and palatally displaced canines: a cone-beam computed tomographic study. Hong W-H, Radfar R, Chung C-H. The Angle Orthodontist. 2015;85(3):440-5. PMID: 25098187
21. Role of homeobox genes in the patterning, specification, and differentiation of ectodermal appendages in mammals. Duverger O, Morasso MI. Journal of cellular physiology. 2008;216(2):337-46. PMID: 18459147