

# Alveolar ridge augmentation in mandible by use the modified distractor

Feras Sulaiman<sup>1</sup>, Issam Alkhouri<sup>1</sup>, Maher Al-assaf<sup>2</sup>

<sup>1</sup> Department of Oral and Maxillofacial Surgery, Faculty of Dentistry, Damascus University, Damascus, Syria

<sup>2</sup> Department of Oral Histology and Pathology, Faculty of Dentistry, Damascus University, Damascus, Syria

## Abstract

**OBJECTIVE:** The aim of the present study was to evaluate the horizontal and the vertical alveolar distraction osteogenesis using modified alveolar distractor.

**STUDY DESIGN:** The sample consisted of 7 patients presenting horizontally and vertically deficient edentulous ridges were treated by distraction osteogenesis with a modified Alveolar distractor. The surgical procedure was carried out with the patient under local anesthesia. After the osteotomy was performed with pizosurgery, the distractor was placed on the segmental bone over the gingiva for 3 months. The rate of distraction was 0.5 mm/twice a day.

**RESULTS:** The mean of horizontal alveolar before using the distractor was 4.70 mm (SD 0.31 mm) The mean of horizontal alveolar after using the distractor was 8.30 mm (Sd 0.59 mm). The mean of actual gain in bone horizontal at the end of the distraction period was 3.58 mm (SD 0.15 mm). The mean of height alveolar before using the distractor was 6.67 mm (SD 0.46 mm) The mean of height alveolar after using the distractor was 12.59 mm (SD 0.52 mm). The mean of actual gain in bone height at the end of the distraction period was 5.92 mm (SD 0.25 mm).

**CONCLUSION:** It was concluded that the modified alveolar distractor seems to be an effective to treat horizontal and vertical alveolar ridge deficiencies, and distraction osteogenesis can be considered a safe and effective procedure for gaining bone in the horizontal and the vertical dimension of the alveolar.

**KEYWORDS:** horizontal alveolar; vertical alveolar; distraction osteogenesis; distractor

Citation: Sulaiman, F et al. (2022) Alveolar ridge augmentation in mandible by use the modified distractor

Dentistry 3000. 1:a001 doi:10.5195/d3000.2022.216

Received: August 2, 2021

Accepted: September 28, 2021

Published: May 9, 2022

Copyright: ©2022 Sulaiman F et al. This is an open access article licensed under a Creative Commons Attribution Work 4.0 United States License.

Email: dr.maher.assaf1990@gmail.com

## Introduction

Some patients may have insufficient bone to place dental implants but there are many surgical techniques to increase the bone volume making implant treatment possible [1]. Bone can be regenerated in a horizontal and vertical direction using various

techniques [2]. A variety of surgical techniques have been described to enhance the bone volume of deficient implant-recipient sites, such as the use of onlay or veneer grafts, ridge splitting, or bone condensation, guided bone regeneration (GBR), alveolar osteogenic distraction (AOD) [3,4].

Alveolar osteogenic distraction (AOD) has been considered a promising procedure for bone augmentation [5]. The AOD is a biological process through which new bone formation occurs between the surfaces of vascularized bone segments that are gradually separated by incremental traction [6]. The bone is initially

sectioned by osteotomy and the separation process is controlled by an osteodistractor device [5]. In this way, the AOD avoids the morbidity associated with the donor site and provides hard- and soft-tissue predictable gain once the alveolar bone gain occurs simultaneously with soft-tissue increase [3]. Moreover, the AOD is associated with low infection rate, decreased bone resorption, and a short period of bone healing, accelerating the treatment finalization [7]. The new bone structure formed by this technique has the same quality and morphology of the maxilla bone, and the use of the autogenous bone graft is not required [8]. AOD involves three phases: osteotomy/latency, activation/distraction and consolidation phases [9]. In general, we can distinguish 2 types of distraction devices: intraosseous and extraosseous [10]. They can also be differentiated depending on their role, dividing them into distractors or distractor-implants [11]. Depending on the direction of the regenerated bone, they are divided into vertical or horizontal distraction devices [12]. Different studies present different distraction protocols for each distractor device [13].

So, the aim of the research was to evaluate the horizontal and the vertical alveolar distraction osteogenesis using modified alveolar distractor.

## Material and Methods

### Study sample

The research sample consisted of 7 patients presenting horizontally and vertically deficient edentulous ridges in the posterior mandibular region. Patients attending the dental implant unit and outpatient clinic of the department of oral and maxillofacial surgery at the Faculty of Dentistry at Damascus University.

### Inclusion criteria

- ✓ Ages of patients from 20 to 55 years old.
- ✓ The patients are healthy and do not have any general diseases.
- ✓ In patients, the loss of one or more teeth in the posterior region of the mandibular.
- ✓ Patients do not have any bad habits such as smoking or clenching.

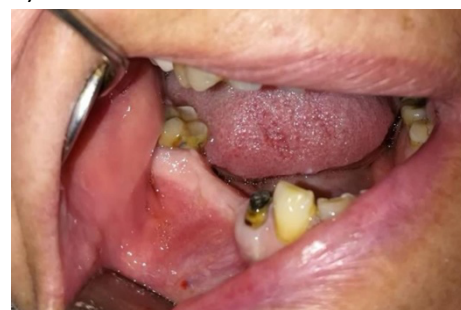### Exclusion criteria

The availability of any of the following conditions is sufficient to exclude the patient from the research:

- ✓ The presence of general diseases or factors that prevent surgery under local anesthesia.
- ✓ Patients with complete tooth loose of the mandibular.
- ✓ Patients have bad habits such as smoking or clenching.
- ✓ Pregnancy.

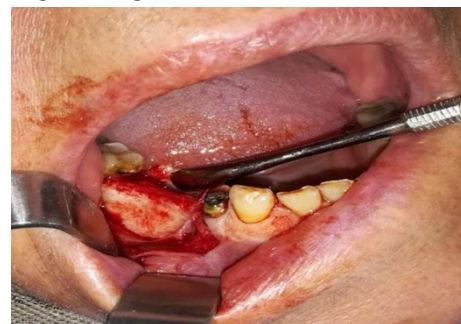## Surgical Procedure

All patients were treated under local anesthesia (2% lidocaine solution with epinephrine 1:100.000). (Figure 2)



**Figure 2.** Initial intraoral image before the alveolar osteogenic distraction.

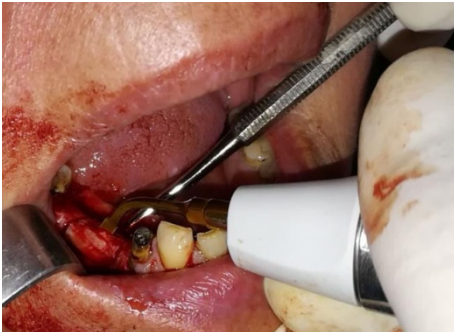Intraoral linear incision with 15C Scalpel Blade was performed on the vestibular region 1 mm above the mucogingival line. Then, one vertical incision rising from the first incision were carried out over the mesial region. A conservative subperiosteal dissection was performed to expose the bone ridge only in the osteotomy region. (Figure 3)



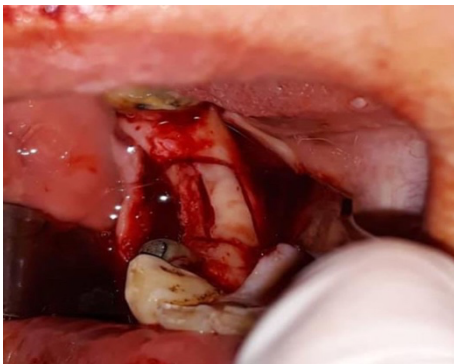
**Figure 3.** The triangle flap.

Osteotomy was performed using a

piezoelectric ultrasonic device.  
(Figure 4,5)

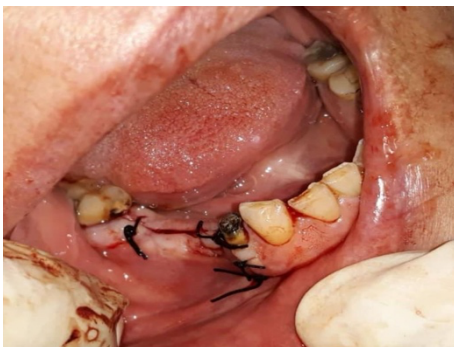

**Figure 4.** The bone osteotomy by Piezo-surgery.

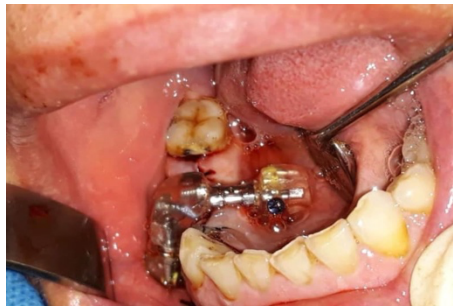

**Figure 5.** The bone fragments.

After performing an osteotomy in the alveolar bone, a distraction device is fixed on the transport segment and the basal bone over the gingiva.  
(Figure 6,7)

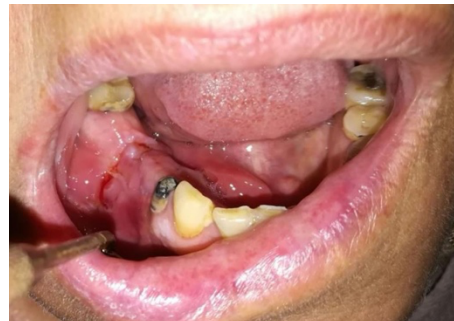

**Figure 6.** The suture.



**Figure 7.** Placement of the modified alveolar distractor

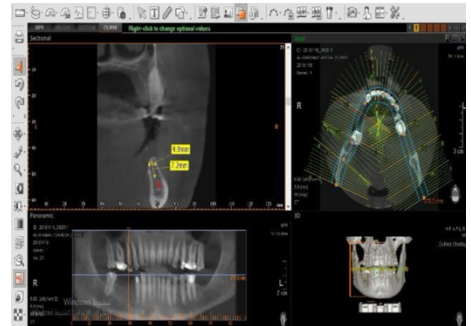
Subsequently, the transport segment is submitted to gradual traction to separate it from the basal bone. The distraction devices were not activated for 7 days to allow periosteal and soft tissue healing and early vascularization. After a latency period of 7 days, distraction devices were activated 0.5 mm twice daily to achieve movement of 1 mm per day. After retention of 12 weeks, distractors were removed under local anesthesia. (Figure 8)



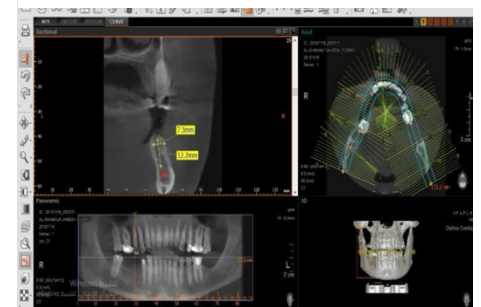
**Figure 8.** Final tissue volume obtained after 3 months of the alveolar osteogenic distraction surgery.

A computed tomography (CBCT) image was performed for each case before the surgery procedure and the measurements were taken on the sections of the surgery site and the patient was followed up and after

three months another CBCT was requested. (Figure 1,9)



**Figure 1.** Initial CBCT radiograph before the alveolar osteogenic distraction.



**Figure 9.** CBCT radiograph after 3 months of the alveolar osteogenic distraction surgery confirming the bone gain obtained.

### Statistical Analysis

Statistical analysis was performed with SPSS (statistical package for the social sciences) v.25 (IBM, New York, NY). Statistical significance level was established at ( $p < 0.05$ ).

The paired t-test was used to evaluate bone dimensional changes (vertical and horizontal) between before and after the alveolar osteogenic distraction surgery.

### Results

Study sample consisted of 7 patients, 1 male and 6 females and the age of the patients ranged between 20 - 55 years with a mean of 32.2 years. Bone

defects were different for each patient and bone ratio was set up depending on patient need. The evaluation of bone ratios was performed depending on the activating times of the distraction devices and supported by radiologic data. Distraction devices were activated twice a day (Table No. 1).

The mean of horizontal alveolar before using the distractor was 4.70 mm (SD 0.31 mm) The mean of horizontal alveolar after using the distractor was 8.30 mm (Sd 0.59 mm). There was a statistically significant difference between timepoints ( $p < 0.05$ ). The mean of actual gain in bone horizontal at the end of the distraction period was 3.58 mm (SD 0.15 mm) (Table No. 2 and Table No. 4).

**Table 1:** Protocol for gradual alveolar distraction osteogenesis of the posterior mandible prior to Device removal.

Surgery	Latency period	Rate of bone elongation	Consolidation period	Device removal
	7 days	0.5 mm/twice a day	3 months	

**Table 2:** Means, standard deviations, and ranges of the width alveolar bone in the distraction osteogenesis (DO).

The width alveolar bone	mean	standard deviations	Minimum	Maximum
Before distraction	4.70	.310	4.00	5.20
After distraction	8.30	0.59	4.00	9.50

**Table 4:** Paired T test for samples to study the change in the width of the alveolar bone before and after 3 months of the distraction osteogenesis (DO).

	T-value	P-value	mean Difference	S.D. of mean Difference	Confidence interval (95%)	
					Lower limit	Upper limit
Horizontal bone gain	-25.922	.000	3.58-	.150	-4.10	-2.89

The mean of height alveolar before using the distractor was 6.67 mm (Sd 0.46 mm) The mean of height alveolar after using the distractor was 12.59 mm (SD 0.52 mm). There was a statistically significant difference between timepoints ( $p < 0.05$ ). The mean of actual gain in bone height at the end of the distraction period was 5.92 mm (Sd 0.25 mm) (Table No. 3 and Table No. 5)

rehabilitation [15]. Different augmentation techniques have been used for reconstruction of alveolar defects for many years, such as autogenous or artificial bone grafts and the split crest technique [16]. These conventional procedures have disadvantages, such as donor site morbidity, unpredictable bone resorption, and difficulty with soft tissue coverage [17]. ADO is an

controlled displacement of a surgically prepared fracture is used to increase bone volume, are not new but have recently been introduced into implant surgery to increase alveolar bone volume [19].

This study included 7 patients were treated by vertical and horizontal alveolar distraction osteogenesis. Alveolar ridge augmentation by DO has become the best alternative for

**Table 3:** Means, standard deviations, and ranges of the height alveolar bone in the distraction osteogenesis (DO).

The Height alveolar bone	mean	standard deviations	Minimum	Maximum
Before distraction	6.67	0.46	5.80	7.50
After distraction	12.59	0.52	11.70	13.40

**Table 5:** Paired T test for samples to study the change in the height of the alveolar bone before and after 3 months of the distraction osteogenesis (DO).

	T value	P value	mean Difference	S.D. of mean Difference	Confidence interval (95%)	
					Lower limit	Upper limit
Vertical bone gain	-51.765	.000	-5.92	0.25	-6.17	-5.67

## Discussion

Vertical and horizontal atrophy of the alveolar region may make implant placement difficult, thus compromising prosthetic

innovative procedure used to avoid donor site morbidity and problems with soft tissue coverage and limited augmentation [18].

The principals of distraction osteogenesis in which a gradual,

preprosthetic surgery instead of using free, microvascular, and alloplastic bone grafts [20]. Reconstruction sites are filled with original bone and soft tissue reconstruction is managed at the same operation [9].

Many authors have emphasized that distractors should not be activated for 5 to 7 days to allow callus formation [6]. During this time, a reparative callus is created, osteogenic cells proliferate, damaged blood vessels are repaired, and revascularization occurs [14,21]. In this study, we waited for 7 days to allow for callus formation, soft tissue, and periosteal healing. A gradual distraction rate of 0.5 mm twice a day [22]. In this way, we achieved painless stretching and appropriate adaptation of alveolar soft and hard tissues.

ADO is an advantageous technique, providing both soft and hard tissue reconstruction with original structures. Taking into account the aspects of radiologic and histologic evaluations, the alveolar bone is considered to be appropriate to receive implants at the twelfth week [23]. The required time for dental implantation is shortened by this technique compared with classical procedures, so the consolidation phase was 12 weeks.

Vertical augmentation is easy to evaluate using standard X-rays, while horizontal augmentation is difficult to evaluate with X-rays and CBCT is necessary. Recently, cone-beam CT (CBCT) has been widely used in dental treatment [24]. CBCT was used to assess bone height and width preoperatively, and finally after consolidation. At the end of the distraction procedures, radiolucent gaps were observed at the distraction

chambers [25]. Twelve weeks after distraction, distraction gaps appeared mostly radio-opaque, but there were still some radiolucent areas.

Evaluation of the dental CT scans, which were performed just before removal of the distractors (12 weeks after distraction), confirmed increase of the alveolar heights and widths and filling of the distraction chambers with bone.

Esposito et al [4] in a systematic review of Cochrane on different vertical regeneration techniques, didn't find sufficient evidence regarding which was the best procedure. However, they reported that the ADO technique has the greatest potential for vertical regeneration procedures.

## Conclusion

With the limitation of this study, we can conclude that the modified alveolar distractor seems to be an effective to treat horizontal and vertical alveolar ridge deficiencies, and distraction osteogenesis can be considered a safe and effective procedure for gaining bone in the horizontal and the vertical dimension of the alveolar. If applied to patients selected carefully using preoperative CBCT, and if performed and managed accurately.

## References

1. Clinical outcomes of vertical bone augmentation to enable dental implant placement: a systematic review. Rocchietta I,

Fontana F, Simion M. *J Clin Periodontol.* 2008 Sep;35(8 Suppl):203-215. doi: 10.1111/j.1600-051X.2008.01271.x. PMID: 18724851.

2. The efficacy of horizontal and vertical bone augmentation procedures for dental implants: a Cochrane systematic review. Esposito M, Grusovin MG, Felice P, Karatzopoulos G, Worthington HV, Coulthard P. *Evidence-based practice: Toward optimizing clinical outcomes.* 2010:195-218. doi: 10.1007/978-3-642-05025-1\_13.
3. Use of alveolar distraction osteogenesis for anterior maxillary defect reconstruction. Marcantonio C, Nicoli LG, Pigossi SC, Araújo RFSB, Boeck EM, Junior EM. *J Indian Soc Periodontol.* 2019 Jul-Aug;23(4):381-386. doi: 10.4103/jisp.jisp\_549\_18. PMID: 31367139.
4. The efficacy of horizontal and vertical bone augmentation procedures for dental implants - a Cochrane systematic review. Esposito M, Grusovin MG, Felice P, Karatzopoulos G, Worthington HV, Coulthard P. *Eur J Oral Implantol.* 2009 Autumn;2(3):167-184. doi: 10.1007/978-3-642-05025-1\_13. PMID: 20467628.
5. Alveolar osteogenic distraction as method to increase the alveolar ridge. Navarro DM. *Revista Cubana de Estomatología.* 2011;48(1):43-55.
6. Alveolar ridge augmentation by distraction osteogenesis. Rachmiel A, Srouji S, Peled M. *International journal of oral and maxillofacial surgery.* 2001 Dec;30(6):510-517. doi: 10.1054/ijom.2001.0134.

7. Alveolar osteogenic distraction as method to increase the alveolar ridge. TNavarro DM. *Revista Cubana de Estomatología*. 2011;48(1):43-55.
8. Alveolar distraction osteogenesis for dental implant treatments of the vertical bone atrophy: A systematic review. Toledano-Serrabona J, Sánchez-Garcés MÁ, Sánchez-Torres A, Gay-Escoda C. *Med Oral Patol Oral Cir Bucal*. 2019 Jan;24(1):e70-e75. doi: 10.4317/medoral.22750. PMID: 30573711.
9. Evaluation of osseous regeneration in alveolar distraction osteogenesis with histological and radiological aspects. Türker N, Basa S, Vural G. *J Oral Maxillofac Surg*. 2007 Apr;65(4):608-614. doi: 10.1016/j.joms.2006.05.057. PMID: 17368352.
10. Vertical bone augmentation of posterior mandibular region: a description of two surgical techniques. Queiroz AG, Silva YS, Costa PJ, Ferraz FW, Naclério-Homem MD. *RGO-Revista Gaúcha de Odontologia*. 2016 Jul;64:333-336. doi: 10.1590/1981-8637201600030000143128.
11. Comparison of intraosseous and extraosseous alveolar distraction osteogenesis. Uckan S, Oguz Y, Bayram B. *J Oral Maxillofac Surg*. 2007 Apr;65(4):671-674. doi: 10.1016/j.joms.2006.04.045. PMID: 17368362.
12. Partially Biodegradable Distraction Implant to Replace Conventional Implants in Alveolar Bone of Insufficient Height: A Preliminary Study in Dogs. Li T, Zhang Y, Shao B, Gao Y, Zhang C, Cao Q, Kong L. *Clin Implant Dent Relat Res*. 2015 Dec;17(6):1164-1173. doi: 10.1111/cid.12229. PMID: 24888978.
13. The reconstructive potential of distraction osteogenesis on defects of the alveolar ridge before dental implants placement: a review. Matoulas E, Nazaroglou I, Kafas P, Charitoudi D. *Research Journal of Medical Sciences*. 2009;3(3):123-132.
14. Morphofunctional and clinical study on mandibular alveolar distraction osteogenesis. Zaffe D, Bertoldi C, Palumbo C, Consolo U. *Clin Oral Implants Res*. 2002 Oct;13(5):550-557. doi: 10.1034/j.1600-0501.2002.130516.x. PMID: 12453134.
15. Implant prosthetic rehabilitation in partially edentulous patients with bone atrophy. An umbrella review based on systematic reviews of randomised controlled trials. Merli M, Moscatelli M, Pagliaro U, Mariotti G, Merli I, Nieri M. *Eur J Oral Implantol*. 2018;11(3):261-280. PMID: 30246181.
16. Comparison of Two Techniques for Lateral Ridge Augmentation in Mandible With Ramus Block Graft. Barbu HM, Andreescu CF, Lorean A, Koleran R, Moraru L, Mortellaro C, Mijiritsky E. *J Craniofac Surg*. 2016 May;27(3):662-667. doi: 10.1097/SCS.0000000000002561. PMID: 27092913.
17. Horizontal ridge augmentation using autogenous block grafts and the guided bone regeneration technique with collagen membranes: a clinical study with 42 patients. von Arx T, Buser D. *Clin Oral Implants Res*. 2006 Aug;17(4):359-366. doi: 10.1111/j.1600-0501.2005.01234.x. PMID: 16907765.
18. Quality and quantity of bone following alveolar distraction osteogenesis in the human mandible. Chiapasco M, Lang NP, Bosshardt DD. *Clin Oral Implants Res*. 2006 Aug;17(4):394-402. doi: 10.1111/j.1600-0501.2005.01247.x. PMID: 16907770.
19. Implant success in distracted bone versus autogenous bone-grafted sites. Elo JA, Herford AS, Boyne PJ. *J Oral Implantol*. 2009;35(4):181-184. doi: 10.1563/1548-1336-35.4.181. PMID: 19813422.
20. Alveolar width distraction osteogenesis for early implant placement. Laster Z, Rachmiel A, Jensen OT. *J Oral Maxillofac Surg*. 2005 Dec;63(12):1724-1730. doi: 10.1016/j.joms.2005.09.001. PMID: 16297692.
21. Biology of Bone Formation, Fracture Healing, and Distraction Osteogenesis. Runyan CM, Gabrick KS. *J Craniofac Surg*. 2017 Jul;28(5):1380-1389. doi: 10.1097/SCS.00000000000003625. PMID: 28562424.
22. Mandibular alveolar ridge augmentation in the dog using distraction osteogenesis. Block MS, Chang A, Crawford C. *J Oral Maxillofac Surg*. 1996 Mar;54(3):309-314. doi: 10.1016/s0278-2391(96)90750-8. PMID: 8600238.
23. Alveolar distraction osteogenesis for bone augmentation of severely atrophic ridges in 10 consecutive cases: a histologic and histomorphometric study. Marchetti C, Corinaldesi G, Pieri F, Degidi M, Piattelli A. *J Periodontol*. 2007 Feb;78(2):360-366. doi: 10.1902/jop.2007.060260. PMID: 17274727.

24. Cone-beam computerized tomography (CBCT) imaging of the oral and maxillofacial region: a systematic review of the literature. De Vos W, Casselman J, Swennen GR. *Int J Oral Maxillofac Surg.* 2009 Jun;38(6):609-625. doi: 10.1016/j.ijom.2009.02.028. PMID: 19464146.
25. Comparing the duration of different phases of vertical alveolar distraction between ultrasound treated and control group in anterior mandible. Al-Kassaby A, Shindy M. *Int J Oral Maxillofac Surg.* 2019 May;48:54. doi: 10.1016/j.ijom.2019.03.163.