



Thermal Pattern Analysis for Detecting Subclinical Inflammation

Hussein Haleem Jasim

¹College of Dentistry, University of Wasit, Iraq

Abstract

Objective: To detect the subclinical and suspected inflammatory tissue changes on the jaws by combining infrared thermography with X-ray radiography. **Materials and Methods:** The study included 150 patients who were referred for panoramic X-rays. Patients selected included 72 males and 78 females, with ages ranging from 18 to 50 years. Infrared thermography (IRT) was applied in the study for screening suspected jaw inflammation. IRT findings were compared with panoramic radiography (a reference standard). After the diagnosis of periapical diseases, each participant in the study was examined thermographically by using an infra-red camera (Teledyne FLIR, Model T560), extra-oral on the face, directed at the maxilla and mandible regions. Thermograms were captured in frontal view, right view, and left view. All thermograms and panoramic radiographs (OPG) were processed and visually enhanced using Fiji ImageJ software for better thermographic and radiographic analysis. The thermographic findings were then compared with the radiographic findings (OPG x-rays). **Results:** The statistical analysis of infrared thermography findings showed that 20% of the cases were positive (inflammatory or suspicious), and 80% of cases were negative (normal pattern). The thermal pattern of infrared thermography showed IRT-positive cases as follows: pulpitis with apical periodontitis 13 (8.7%), acute periapical abscess 9 (6.0%), chronic periapical abscess 5 (3.3%), and suspected 3 (2%). The last three suspected cases were unspecified and considered as IRT-positive cases (inflammatory or suspicious). When IRT findings were compared with OPG findings, they showed a sensitivity of 92.6%, a specificity of 95.9%, and an accuracy of 95.3%. Analysis also showed good agreement between IRT and OPG findings (Cohen's $\kappa = 0.848$), and disagreement was limited (FP = 5 vs FN = 2). For two modalities, analysis showed no significant difference in paired positive and negative classifications (exact McNemar test, $p = 0.453$). **Conclusion:** Thermal pattern analysis in the orofacial region can be helpful for the early detection of inflammatory or suspected diseases as a supplement to radiography for confirming positive or suspicious findings.

Open Access

Citation: Jasim HH. (2026) Thermal Pattern Analysis for Detecting Subclinical Inflammation. Dentistry 3000. 1:a001 doi:10.5195/d3000.2026.1179
Received: February 18, 2026
Accepted: February 19, 2026
Published: April 7, 2026
Copyright: ©2026 Jasim HH. This is an open access article licensed under a Creative Commons Attribution Work 4.0 United States License.
Email: halmhanawi@uowasit.edu.iq

Introduction

Thermal imaging cameras are used to detect infrared emissions released by objects. It transduces this thermal (heat) energy into a visible representation. As the thermal level rises, the

amount of infrared (IR) radiation increases, and the object appears brighter on the infrared thermogram [1]. In humans, most bioenergetic output is released as heat through the skin via radiation, heat conduction, convective heat transfer, and evaporative heat loss, radiation

being the most efficient, so thermal images can serve as an indirect indicator of tissue metabolism. Thermal homeostasis involves autonomic control of blood flow and vascular constriction [2]; therefore, skin temperature depends on blood temperature and blood flow, and any

factor affecting vasodilation and vasoconstriction (e.g., injury or disease) shifts infrared output [3]. Unlike many imaging modalities that detect pathological lesions after structural damage is confirmed, infrared thermography (IRT) may detect functional alterations before obvious lesions appear; however, image interpretation must consider endogenous influences (thermoregulation, metabolic processes, circadian rhythms, thermal balance, physiological activity, and emotions) and exogenous influences (environmental temperature, humidity, and airflow). Under normal conditions, bilateral thermal symmetry is expected, with higher temperatures over the head/neck/torso than limbs; higher adipose tissue may lower skin-surface temperature (reducing diagnostic accuracy in marked obesity), and females tend to show slightly higher surface temperatures than males. Thermograms or thermal images should be interpreted alongside clinical signs and symptoms for accurate anatomical localization, ideally by comparing current images with the patient's reference baseline (pre-illness) thermogram; for example, breast thermal imbalance may suggest underlying pathology [4], and a confined, slight temperature decrease can be an early indicator of pressure-related injury [5]. With improved sensitivity and usability, IRT has expanded medical fields, offering non-invasive, portable, simple, cost-effective evaluation [6] without ionizing radiation, and it can be an adjunct to conventional or standard imaging (e.g., X-ray, CT, Ultrasound) for multimodal verification. IRT acquires thermal surface patterns by detecting infrared (IR) radiation from the body; based on Pennes' bioheat model, skin temperature mirrors metabolic activity and localized blood flow [7]. Because persistent inflammation and impaired insulin sensitivity (key features of metabolic syndrome) can modulate thermogenesis and vascular function [8-11], these changes may appear as distinctive global thermal distributions—particularly on palmar and facial areas (Figure 1). While earlier work often emphasized focal temperature changes in cases such as peripheral vascular disorder [12-16], more recent developments support the diagnostic performance of overall thermal patterns for metabolic diseases including hypertension and diabetes [14-17]. In dentistry, infrared thermography has been applied in multiple frameworks: temporomandibular disorders and chronic orofacial pain have been successfully categorized using facial thermography [18,19]. It has also been applied to assess thermal injury to the tooth pulp; thermogram assessment showed marked dental pulpal temperature increases after electrothermal bracket debonding of orthodontic brackets,

emphasizing potential pulpal risk [20]. Photo-thermal lock-in imaging based on heat wave principles has been shown to have utility for detecting incipient caries [21]. Beyond dentistry, thermography and other photothermal imaging approaches have been used to detect malignant tumors in human soft and hard tissues [22,23]. In oral oncology, particularly, an inexpensive portable infrared device revealed high discrimination between oral cancer and pre-cancer in a double-blind trial, reaching specificity of 100% and sensitivity of 96.66% compared with biopsy [24]. Furthermore, in a pre-planned trial study of 90 oral cancer patients with presumed cervical lymph node metastasis, a computer-aided SVM-based model-driven infrared system showed higher accuracy, specificity, and sensitivity than CT and manual descriptive evaluation, supporting its potential as a non-ionizing, non-invasive substitute approach for detecting lymph node metastasis [25]. Error! Reference source not found.

Material and Methods

The current study included 150 patients, selected in a random manner, referred for panoramic radiography. They comprised 72 males and 78 females, aged from 18 to 50 years. The study was conducted in Baghdad, Iraq, in several dental centers, from September 2017 to March 2020. Infrared thermography (IRT) was applied in the study for screening suspected inflammation in the jaws. The IRT findings (Figure 1) were compared with panoramic radiography (reference standard). Infrared thermography (IRT) was applied for screening suspected jaw inflammation, which may be unobserved or hidden on OPG x-rays, and the findings were compared with panoramic radiography (OPG) as the radiographic diagnostic reference (reference standard). The study highlighted periapical diseases to be included, which were classified into three categories: AAP (pulpitis with apical periodontitis), AA (acute periapical abscess), and CA (chronic periapical abscess). Radiographic examination was supported by clinical examination for detecting symptoms and signs of periapical diseases. The diagnoses of periapical diseases were performed independently by two experienced investigators. A third senior investigator resolved the disagreements between the two investigators. After the diagnosis of periapical diseases was confirmed, each participant in the study was examined thermographically by using an Infra-red Camera (Teledyne FLIR, Model T560) through extraoral imaging on the face, directed at the maxilla and mandible regions with the mouth closed. Infrared thermography (IRT) was performed to identify

thermal signatures suggestive of periapical inflammation. Thermograms were captured in frontal, right, and left views. The IRT outcomes were either registered as a positive sign (thermographic pattern or hotspot) representing suggestive inflammatory activity, or a negative sign showing no suggestive inflammation (registered as a normal thermal pattern). All thermograms and panoramic radiographs (OPGs) were processed and visually enhanced using Fiji ImageJ software for improved thermographic and radiographic analysis [26], which was maintained consistently in all cases to ensure reproducibility. The thermographic findings were then compared with the radiographic findings (OPGs). All participants were informed of the study's purpose. Thermograms were captured at a room temperature within the range of (20-24 °C) and humidity of 40–60%. The emissivity parameters of the human body used to calibrate the infrared camera were ϵ : 0.98 and Spectral range: 7.5–14.0 μm . All these standards are important for minimizing the thermal variability. Patients avoided vigorous exercise, smoking, facial washing, drinking and eating for 60 minutes pre-procedure. Participants were acclimated to the same room 15-20 minutes before the scan. The resolution of thermal images was set at 90 x 120 pixels. Thermography was performed on a uniform dark matte background. Artificial lights were switched off, all electronic devices were kept ≥ 2 m from the participants, and window openings and reflective bright surfaces were covered with dark opaque clothing. Odontogenic facial cellulitis, abscess, active sinusitis, lymphadenitis, parotitis, otitis, or major URTI symptoms, symptomatic active temporomandibular disorders, symptomatic pericoronitis, facial skin diseases, face covered by cosmetics, cream or oil that can affect emissivity, severe symptomatic gingivitis and periodontal abscess, pregnancy, patients on anti-inflammatory drugs and analgesics within the last 24 hours, smoker and alcoholic patients, recent dental surgery, facial trauma, surgery, fillers, or injections in last 4 weeks and poor quality thermograms and panoramic radiographs were not included in the study. The statistical analysis was executed using SPSS 29, as follows: Measurements of diagnostic accuracy metrics (Sensitivity, specificity, PPV, NPV, accuracy). The exact McNemar Test (two-sided) was applied to compare discordant classifications (FP vs FN) between IRT and OPG within the same individuals. Cohen's Kappa (κ) was used to measure the agreement between IRT and OPG beyond chance. Confidence Intervals (95%) were used to determine the precision of diagnostic performance

metrics (sensitivity, specificity, accuracy and predictive values).

Results

A total of 150 participants were included (72 males, 48.0%; 78 females, 52.0%), with an average age of 34.00 ± 9.24 years. The data analyzed for both panoramic radiography diagnostic outcomes (as the reference standard) and Infrared thermography screening findings. The statistical analysis showed that panoramic radiography identified 27 of 150 subjects (18.0%) with pathological cases, and 123 of 150 subjects (82.0%) were recorded as normal cases. The pathological cases in panoramic (OPG) images were distributed as: AAP, 13 (8.7%); AA, 9 (6.0%); and CA, 5 (3.3%). In contrast, infrared thermography showed that 20% of the cases (30/150) were positive (inflammatory), and 80% of cases (120/150) were negative (normal pattern). The thermal pattern of infrared thermography showed IRT-positive cases as follows: AAP 13 (8.7%), AA: 9 (6.0%), CA: 5 (3.3%), and the remaining 3 (2%) were unspecified, considered as IRT-positive cases. (Inflammatory-suspicious).

Using OPG as the reference standard, IRT identified 30 positive cases (inflammatory) among 150 subjects (20%) and identified 120 negative cases (normal). Within the IRT-positive group, 3 cases (2% of the total sample) showed an abnormal thermal pattern and were recorded as suspected cases. Panoramic radiography (OPG) identified periapical pathology in 27 cases (18.0%); out of these, infrared thermography identified 25 cases (sensitivity 92.6%) and failed to identify 2 cases (7.4%). Within the 123 cases with normal OPG findings (82%), IRT identified 118 as negative (specificity 95.9%) and produced 5 false-positive IRT results among OPG-negative cases (4.1%). These five false positives comprised two additional IRT-positive findings and three suspected cases with thermal patterns, which represent false positives relative to the OPG reference (with no OPG evidence).

The statistical analysis of IRT findings compared with OPG showed a sensitivity of 92.6%, a specificity of 95.9%, and an accuracy of 95.3%. Analysis also showed good agreement between IRT and OPG findings in 143 of 150 subjects (Cohen's $\kappa = 0.848$), and disagreement was limited (FP = 5 vs FN = 2). The negative predictive value (NPV) was high at 98.3% (118 of 120 IRT-negative subjects were also OPG-negative (NPV 98.3%). In positive infrared imaging results, panoramic radiographs revealed the presence of the disease in 25 out of 30 cases (PPV: 83.3%). The analysis showed no statistically significant difference between

the two testing methods in the classifications of dual positive/negative results (Exact McNemar test, $p = 0.453$).

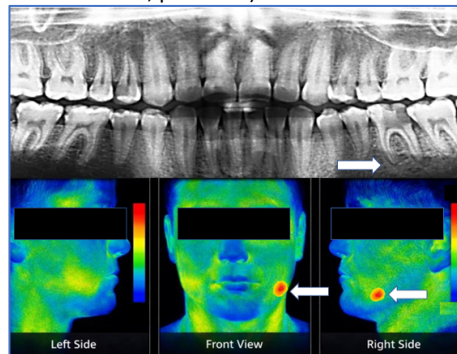


Figure 1. Panoramic radiograph with a thermal pattern suggestive of periapical inflammation.

Discussion

Infrared thermography (IRT) is a non-invasive imaging approach that profiles skin surface temperature distributions, which can reflect underlying vascular and inflammatory activity, and provide functional thermal data. Therefore, according to these facts, infrared thermography can support traditional dental evaluations. The current study introduced infrared thermography for detecting subclinical and suspected inflammatory tissue changes in the jaws. The study combined infrared thermography with panoramic radiography for the detection of periapical diseases, and the panoramic radiographs were considered the standard reference.

Many studies have coupled infrared thermography in dental practice; one study has been assessed in endodontics as a quantitative supplement for periapical inflammatory pathologies and suggested detectable thermal differences among diagnostic categories [27]. Other studies also included infrared thermography as an adjunctive screening indicator in high-risk patients to identify subclinical odontogenic infection foci, which depend on localized temperature variations or thermal imbalance [28,29]. Infrared thermography has also been used in another study to assess postoperative inflammation and healing progression after the removal of impacted wisdom teeth by monitoring temperature changes over time [30]. In temporomandibular disorders (TMD), the data are inconsistent, and a systematic literature review demonstrated marked variation and risk of bias between studies. Clinical research has shown limited diagnostic discrimination, indicating IRT should be considered only an adjunctive tool rather than a definitive diagnostic test [31,32].

In our study, panoramic radiography (OPG) identified 27 of 150 subjects (18%) with periapical pathology, and 123 of 150 subjects (82%) were recorded as normal cases. The pathological cases in panoramic (OPG) images were distributed as: AAP, 13 (8.7%); AA, 9 (6%) and CA, 5 (3.3%). In contrast, infrared thermography (IRT) showed that 20% of the cases (30/150) were positive (inflammatory or suspicious), and 80% of cases (120/150) were negative (normal pattern). The thermal pattern of infrared thermography showed positive cases as follows: AAP 13 (8.7%), AA: 9 (6%), CA: 5 (3.3%), Suspected: 3 (2%), and the last three suspected cases were unspecified and considered IRT-positive cases (Inflammatory or suspicious). The negative predictive value (NPV) was very high, at 98.3%. This result is clinically most important in our study; in 120 IRT-negative subjects, there were also 118 OPG-negative, and a normal thermal pattern made OPG-detectable pathology unlikely. The positive predictive value (PPV) was 83.3%, which is lower than NPV, because IRT involved a small number of positive cases in OPG-negative subjects (5/150, 3.3%), which naturally reduces the PPV, especially since OPG-detectable pathology is relatively low (18%). Notably, three of these cases (3/150, 2%) were identified as "suspicious" because they had an abnormal thermal pattern in thermograms, which were still recorded as negative results on OPG and were considered as IRT-positive (inflammatory/suspicious) for analysis. The suspicious findings (2%) can be interpreted in either of two reasonable ways: First, they may suggest early functional inflammatory changes that affect facial temperature before structural changes become visible on panoramic imaging. Second, they may represent non-specific thermal variations related to several factors, such as technical factors, standardization of acquisition conditions and ROI placement, as well as soft tissue conditions, environmental influences, and normal perfusion differences. The statistical analysis of IRT findings showed good overall performance of IRT, compared with OPG, with a sensitivity of 92.6%, specificity of 95.9%, and accuracy of 95.3%. The analysis also showed that agreement between the findings of two modalities was strong (Cohen's $\kappa = 0.848$), and disagreement was limited (FP = 5 vs FN = 2), referring to IRT was slightly more likely to mark positives in OPG-normal cases than to miss OPG-positive findings, which supports a screening role where missing disease should be minimized. The analysis showed no significant difference in paired positive/negative classifications between the two modalities in our sample (exact

McNemar test, $p = 0.453$). These results generally support IRT as a useful supplementary tool with high ability to exclude disease.

Clinically, according to our findings, some cases identified by infrared thermography (IRT-positive and OPG-negative) may indicate early inflammatory changes that are still not radiographically evident. This emphasizes importance of further assessment supported by new studies in specific cases, such as clinical endodontic tests, when necessary, and high-resolution imaging to determine whether some false positives may be early clinically significant pathology that was not detected by panoramic radiography. Moreover, IRT does not provide anatomical information such as the size of the lesion, its borders, or its relationship to the maxillary sinus/canal, or a radiographic differential diagnosis, which is why radiography remains essential.

Conclusion

Infrared thermography showed a high level of agreement with panoramic radiography and a reliable ability to rule out periapical pathology that was detectable on OPG when the thermal pattern was normal. The study showed minimal disagreement between two modalities, which were primarily defined in some cases by marking suspected inflammation on thermography that appeared normal on OPG, which may be due to either early functional changes undetectable on radiographs or non-specific thermal variations. These results generally support IRT as a useful supplementary tool to dental radiography, but this does not overlook the need for clinical correlation and proper imaging for confirmation of positive or suspicious findings.

Ethical Approval

All procedures in the current study complied with the Declaration of Helsinki. The study was carried out according to the standards of the Ethics Committee for Scientific Research at the College of Dentistry - University of Wasit, in October 2024. All participants in the study signed a formal consent form before the commencement of the study.

Financial Support and Sponsorship

None.

Conflicts of interest

No conflicts of interest.

References

- Sarhadi A, Albuquerque RQ, Demleitner M, Ruckdäschel H, Eder MA. Machine learning based thermal imaging damage detection in glass-epoxy composite materials. *Compos Struct.* 2022;295:115786. doi:10.1016/j.compstruct.2022.115786.
- Madden CJ, Morrison SF. Central nervous system circuits that control body temperature. *Neurosci Lett.* 2019;696:225-232. doi:10.1016/j.neulet.2018.11.027.
- Cramer MN, Gagnon D, Laitano O, Crandall CG. Human temperature regulation under heat stress in health, disease, and injury. *Physiol Rev.* 2022 Oct 1;102(4):1907-1989. doi:10.1152/physrev.00047.2021
- Husaini MASA, Habaebi MH, Hameed SA, Islam MR, Gunawan TS. A systematic review of breast cancer detection using thermography and neural networks. *IEEE Access.* 2020;8:208922-37.
- Cai F, Jiang X, Hou X, Wang D, Wang Y, Deng H, Guo H, Wang H, Li X. Application of infrared thermography in the early warning of pressure injury: a prospective observational study. *J Clin Nurs.* 2021;30:559-71.
- Aydemir U, Sarigoz T, Ertan T, Topuz Ö. Role of digital infrared thermal imaging in diagnosis of acute appendicitis. *Turk J Trauma Emerg Surg.* 2020;27:647.
- Geerling JJ, Boon MR, Kooijman S, Parlevliet ET, Havekes LM, Romijn JA, Meurs IM, Rensen PCN. Sympathetic nervous system control of triglyceride metabolism: novel concepts derived from recent studies. *J Lipid Res.* 2014 Feb;55(2):180-189. doi:10.1194/jlr.R045013. Epub 2013 Nov 27.
- Singh D, Singh AK. Role of image thermography in early breast cancer detection—past, present and future. *Comput Methods Programs Biomed.* 2020;183:105074. doi:10.1016/j.cmpb.2019.105074.
- De Camargo VMB, Ulbricht L, Coninck JCP, Ripka WL, Gamba HR. Thermography as an aid for the complementary diagnosis of nodules in the thyroid gland. *Biomed Eng Online.* 2022;21(1):41. doi:10.1186/s12938-022-00994-0.
- Collins AJ, Ring EFJ, Cosh JA, Bacon PA. Quantitation of thermography in arthritis using multi-isothermal analysis. I. The thermographic index. *Ann Rheum Dis.* 1974;33(2):113-115. doi:10.1136/ard.33.2.113.
- Schlager O, Gschwandner ME, Herberg K, Froehlich H, Schillinger M, Trubel W, et al. Correlation of infrared thermography and skin perfusion in Raynaud patients and in healthy controls. *Microvasc Res.* 2010;80(1):54-57. doi:10.1016/j.mvr.2010.01.010.
- Arteaga-Marrero N, Hernández-Guedes A, Ortega-Rodríguez J, Ruiz-Alzola J. State-of-the-art features for early-stage detection of diabetic foot ulcers based on thermograms. *Biomedicines.* 2023;11(12):3209. doi:10.3390/biomedicines11123209.
- Zhang WZ, Jiang BY, Ye C, Xue HZ, Yang YM, Zhang H, et al. Preliminary study of finger temperature recovery in patients with diabetes mellitus following cold stimulation. *Diabetes Metab Res Rev.* 2024 Jan;40(1):e3706. doi:10.1002/dmrr.3706.
- Gao MJ, Xue HZ, Cai R, Jiang BY, Mi BH, Chen ZJ, et al. A preliminary study on infrared thermograph of metabolic syndrome. *Front Endocrinol (Lausanne).* 2022 Apr 12;13:851369. doi:10.3389/fendo.2022.851369.
- Thiruvengadam, J. & Mariamichael, A. A preliminary study for the assessment of hypertension using static and dynamic IR thermograms. *Biomed Tech (Berl).* 2018;63(2):197-206. doi:10.1515/bmt-2016-0237.
- Thiruvengadam J, Anburajan M, Menaka M, Venkatraman B. Potential of thermal imaging as a tool for prediction of cardiovascular disease. *J Med Phys.* 2014 Apr;39(2):98-105. doi:10.4103/0971-6203.131283.
- Zhang WZ, Jiang BY, Ye C, Xue HZ, Yang YM, Zhang H, et al. Preliminary study of finger temperature recovery in patients with diabetes mellitus following cold stimulation. *Diabetes Metab Res Rev.* 2024 Jan;40(1):e3706. doi:10.1002/dmrr.3706
- Gratt BM, Anbar M. Thermology and facial telethermography: Part II Current and future clinical applications in dentistry. *Dento Maxillofac Radiol.* 1998;27:68-74. doi: 10.1038/sj.dmf.4600324.
- Gratt BM, Graff-Radford SB, Shetty V, Solberg WK, Sickles EA. A 6-year clinical assessment of electronic facial thermography. *Dentomaxillofac Radiol.* 1996;25:247-255. doi: 10.1259/dmfr.25.5.9161178.
- Cummings M, Biagioni P, Lamey PJ, Burden DJ. Thermal image analysis of electrothermal debonding of ceramic brackets: an in vitro study. *Eur J Orthod.* 1991;21:111-118. doi: 10.1093/ejo/21.2.111.
- Tabatabaei N, Mandelis A, Amaechi BT. Thermophotonic lock-in imaging of early demineralized and carious lesions in human teeth. *J Biomed Opt.* 2011;16(7):071402. doi: 10.1117/1.3564890.
- Bonmarin M, Le Gal FA. Lock-in thermal imaging for the early-stage detection of cutaneous melanoma: a feasibility study. *Comput Biol Med.* 2014;47:36-43. doi: 10.1016/j.compbiomed.2014.01.008.]
- Zhang H, Tavakolian P, Sivagurunathan K, Mandelis A, Shi W, Liu FF. Truncated-correlation photo-thermal coherence tomography derivative imaging modality for small animal in vivo early tumor detection. *Opt Lett.* 2019;44(3):675-678. doi: 10.1364/OL.44.000675.
- Bhowmik A, Ghosh B, Pal M, Paul RR, Chatterjee J, Chakraborty S. Portable, handheld, and affordable blood perfusion imager for screening of subsurface cancer in resource-limited settings. *Proc Natl Acad Sci U S A.* 2022;119(2): e2026201119. <https://doi.org/10.1073/pnas.2026201119>.
- Dong F, Tao C, Wu J, et al. Author Correction: Detection of cervical lymph node metastasis from oral cavity cancer using a non-radiating, noninvasive digital infrared thermal imaging system. *Sci Rep.* 2018 Jul 10;8(1):10624. doi:10.1038/s41598-018-28632-2.
- Schindelin J, Arganda-Carreras I, Frise E, Kaynig V, Longair M, Pietzsch T, et al. Fiji: an open-source platform for biological-image analysis. *Nat Methods.* 2012;9(7):676-682. doi:10.1038/nmeth.2019.
- Aboushady MA, Talaat W, Hamdoon Z, Elshazly TM, Ragy N, Bourauef C, et al. Thermography as a non-ionizing quantitative tool for diagnosing periapical inflammatory lesions. *BMC Oral Health.* 2021;21(1):260. doi:10.1186/s12903-021-01618-9.
- Wziątek-Kuczmik D, Niedzielska I, Mrowiec A, Bałamut K, Handzel M, Szurko A. Is Thermal Imaging a Helpful Tool in Diagnosis of Asymptomatic

- Odontogenic Infection Foci—A Pilot Study. *Int J Environ Res Public Health*. 2022;19(23):16325. doi:10.3390/ijerph192316325.
29. Wziątek-Kuczmik D, Mrowiec A, Niedzielska I, Stanek A, Cholewka A. Registration of thermal images of dead teeth to identify odontogenic infection foci. *Sci Rep*. 2024 Sep 13;14(1):21405. doi:10.1038/s41598-024-72565-y.
30. Kasprzyk-Kucewicz T, Cholewka A, Bałamut K, et al. The applications of infrared thermography in surgical removal of retained teeth effects assessment. *J Therm Anal Calorim*. 2021;144(1):139-144. doi:10.1007/s10973-020-09457-6.
31. De Melo DP, Bento PM, Peixoto LR, Martins SKLD, Martins CC. Is infrared thermography effective in the diagnosis of temporomandibular disorders? A systematic review. *Oral Surg Oral Med Oral Pathol Oral Radiol*. 2019;127(2):185-192. doi:10.1016/j.oooo.2018.09.006.
32. Barbosa JS, Amorim AMAM, Arruda MJALLA, Medeiros GBS, Freitas APLF, Vieira LEM, et al. Infrared thermography assessment of patients with temporomandibular disorders. *Dentomaxillofac Radiol*. 2020;49(4):20190392. doi:10.1259/dmfr.20190392.